

# Diagnostic Imaging Features of Various Affections of Udder and Teat in Goats

Aaquib Hussain Paray, Jignesh J. Parmar\*, Arnold R. Mecvan, Prashant B. Dabhi, Pinesh V. Parikh

## ABSTRACT

The present study was carried out on 30 goats with various udder and teat affections. The diagnostic imaging modalities comprised of plain, positive, negative and double contrast radiographic, and ultrasonography of healthy as well as affected udder and teat. Radiography and ultrasonography were effective tools for diagnosis of various affections of teat and udder of goat. Double contrast technique among the plain, negative and positive contrast radiography, and water-bath technique among ultrasonography were most suitable for diagnosis of various teat affections in goats.

**Key words:** Diagnostic Imaging, Goat, Radiography, Teat, Udder, Ultrasonography.

*Ind J Vet Sci and Biotech* (2023): 10.48165/ijvsbt.19.5.05

## INTRODUCTION

The udder is responsible for milk production and milk is an important source of income to the farmers. The quality and quantity of milk are directly affected by various conditions of udder and teat of animals. The goat's udder is an exocrine epithelial gland in the inguinal region with two glands, one on either side of the midline. Udder and teat health are increasingly important for dairy producers and any disease condition involving udder or teat ultimately affects the productivity and the farmer's economy. The udder and teats are vulnerable to external trauma or injury because of their anatomical location, browsing habit of goats, and increase in size of udder and teats during lactation (Abd-El-Hady, 2015). Early diagnosis and treatment of udder and teat disorders is very important to maintain their health. The conventional diagnostic modules like inspection, palpation, probing and hand milking of the affected teat, contrast radiography and ultrasonography are useful to early detections of diseases. Any delay in diagnosis ultimately leads in late treatment of surgical affections of the udder and teat that lead to mastitis or even necrosis of the teat and also affect the economy of farmers, that is why they are getting more attention now a days as an emergency for the therapeutic management (Singh *et al.*, 2003).

Mammography is special term used in radiology means examination to investigate the internal structure of mammary gland, pattern of intra-mammary duct system (Atiya, 2009). Radiography of teat with contrast media prior to surgery improves the prospects of complete removal of obstruction and restoration of normal flow of milk, and it helps in detection of udder fibrosis. Mammary ultrasonography is an efficient technique to evaluate the size and internal consistency which in turn reflects the health status of the mammary gland. The technique is helpful to rule out

Department of Veterinary Surgery and Radiology, College of Veterinary Science and Animal Husbandry, Kamdhenu University, Anand - 388001, Gujarat, India

**Corresponding Author:** Jignesh J. Parmar; Department of Veterinary Surgery and Radiology, College of Veterinary Science and Animal Husbandry, Kamdhenu University, Anand - 388001, Gujarat, India, E-mail: jigneshparmar2000@gmail.com

**How to cite this article:** Paray, A. H., Parmar, J. J., Mecvan, A. R., Dabhi, P. B., & Parikh, P. V. (2023). Diagnostic Imaging Features of Various Affections of Udder and Teat in Goats. *Ind J Vet Sci and Biotech*. 19(5), 27-32.

**Source of support:** Nil

**Conflict of interest:** None

**Submitted:**23/06/2023 **Accepted:**30/07/2023 **Published:**10/09/2023

pathological alterations occurring in mammary glands such as preclinical mastitis (Sethilkumar *et al.*, 2020). The diagnosis and treatment of mastitis in small ruminants is undoubtedly important for economic, aesthetic and welfare points of view. By screening through the available literature, the diseases of udder and teats are well documented in cattle and buffaloes, but very little information is available in small ruminants. So this study was aimed to assess the diagnostic imaging features of various affections of udder and teat in goats.

## MATERIALS AND METHODS

The present study was undertaken on 30 non-descript female goats, irrespective of age, presented with various affections of udder and teats at the Department of Veterinary Surgery and Radiology, College of Veterinary Science and Animal Husbandry, Kamdhenu University, Anand from October 2020 to July 2021. The goats with various affections of udder (n=20) and teats (n=10) included mastitis and fibrosis of udder

(06, each), gangrenous mastitis (04), wounds on udder (02), and oedema of udder and udder abscess (01, each), teat obstruction (04), teat fistula (03), growth on teat (02) and teat laceration (01). The animals were restrained in lateral recumbancy for plain, negative, positive and double contrast radiography, and in lateral recumbancy or standing position for ultrasonography.

Mammary gland radiographic studies were carried out in all 30 goats affected with udder and teat disorders using CXDI-401C Compact Digital Radiography (DR) System (Canon) for plain radiography, positive contrast radiography by using Iohexol 350 mg (10 ml per quarter), negative contrast using room air (90-100 cc per quarter), double contrast radiography by using room air (90-100 cc per quarter, after removal of positive contrast from teat) to rule out the pathological conditions. The contrast material was injected into teat and udder through teat orifice after milking through the polyethylene tube (Ryle's feeding tube No. 6) and was capped to prevent leakage of contrast media. The radiographs were analysed for pathological findings present, if any.

The ultrasonographic study was carried out in normal udders and teats of six healthy goats and 30 goats affected with udder and teat after restraint in a lateral recumbancy or in standing position. B-mode two-dimensional ultrasonography of udder and teat was carried out on Sonosite Titan ultrasonography machine using linear transducer with a frequency of 5-10 MHz. The udders were scanned by direct contact and teats were scanned by water-bath technique by using 7.5-10 MHz linear rectal probe.

## RESULTS AND DISCUSSION

### Radiography of Udder

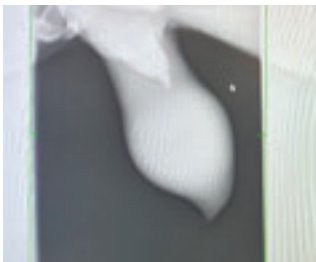In cases of mastitis, plain radiography revealed no difference in radio-opacity of udder and teats filled with milk and/or with flakes (pus) (Fig. 1). The contrast studies of these cases showed uniformity and did not clearly differentiate from normal udder. In the goats affected with fibrosis of udder, plain radiography revealed no clear demarcations which can show extent of fibrosis in udder parenchyma. Complete fibroses in a left quarter in positive contrast appeared as a radio-opaque mass, there was also congenital hypermastia with blind teat with no teat lumen. The positive contrast

study did not differentiate fibrotic and normal tissue (Fig. 2). The negative contrast radiography revealed whether it's complete fibrosis or partial fibrosis of udder tissues and also differentiated between radio-opaque udder and gland cistern (Fig. 3). Double contrast showed the complete radio-dense septum between left fibrotic and right normal udder parenchyma (Fig. 4). Jahangirbasha *et al.* (2016) recorded a radio opaque mass on survey radiography of the right fibrosed gangrenous mastitis quarter in a four-year old goat indicative of fibrosis and calcification.

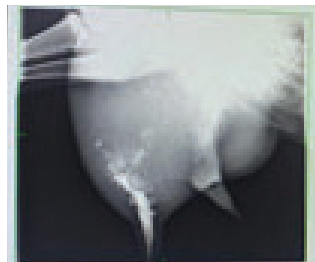
In cases of goats affected with gangrenous mastitis plain radiography revealed appearance of the udder parenchyma resembling normal udder tissues. The positive contrast and negative contrast radiography gave conformation by radiolucent air bubbles (gas bubbles due to gas forming bacteria) in radio-opaque udder parenchyma (Fig. 5, 6). The double contrast radiography revealed same as negative radiography, but with better quality and high definition. The plain radiography of udder in goats with oedema revealed radio-opacity (Fig. 7), which might be due to increased thickness or volume. A case of unilateral udder oedema showed high radio-opacity than normal, but other half was radio-lucent might be due to hypoplasia of udder parenchyma. The positive, negative and double contrast radiographic studies of udder oedema did not have any key features and resembled almost similar to findings of mastitis. In the goat presented with abscess in udder, the plain radiograph showed radio-opaque round structures in between udder halves, In this case of multiple abscess the contrast radiographs showed much more radio-opaque round structures, which might be due to connection of abscesses with that of teat canal. Positive and negative contrast radiographs showed multiple round radio-opaque structures (Fig. 8).

### Radiography of Teat

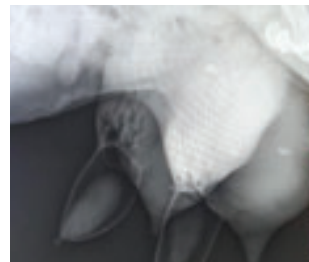
In the goats affected with teat obstruction in streak canal, the plain radiography did not reveal any radiographic abnormality. Teat spider in positive contrast radiograph appeared radiolucent bands in teat cistern, while in double contrast radiograph it showed radio-opaque membranous folds in teat cistern. Teat obstructions mainly as teat spider in negative contrast appeared as radio-opaque pillars



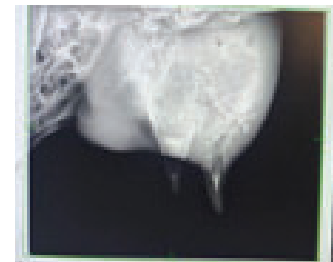
**Fig. 1:** Plain radiograph of mastitic udder



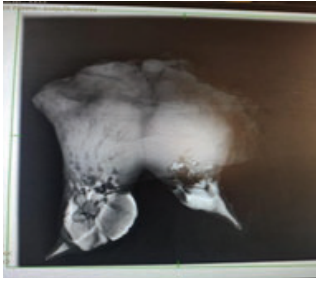
**Fig. 2:** Positive contrast radiograph of fibrotic udder



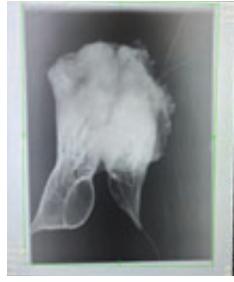**Fig. 3:** Negative contrast radiograph of fibrotic udder



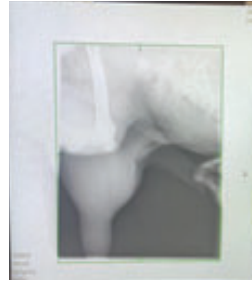**Fig. 4:** Double contrast radiograph of fibrotic udder



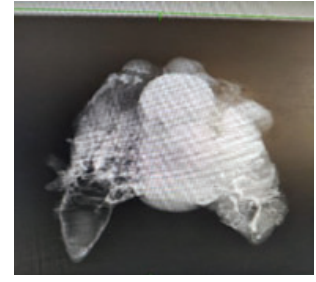
**Fig. 5:** Positive contrast of gangrenous udder



**Fig. 6:** Double contrast of gangrenous udder



**Fig. 7:** Plain radiograph of udder oedema



**Fig. 8:** Double contrast radiography of udder abscess

arising from gland cistern in radiolucent teat cistern, the teat wall also appeared as radio-opaque (Fig. 9) which was not differentiated on plain radiograph. The double contrast radiographic findings appeared as negative radiography but with advantages of confirmation with better quality, high definition. The radiographic findings of teat obstructions such as teat spider and complete fibrous obstruction in middle of teat were similar to findings of Singh *et al.* (1975). Alacam *et al.* (1990) diagnosed complete teat obstructions and congenital obstructions radiographically. In one case growth near Rosette of Furstenberg was also confirmed by double contrast radiography (Fig. 10) over plain, positive or negative radiographic studies, which did not give any clue. Thus the double contrast radiography was found to be fruitful for any type of intra-luminal or intramural defects. In the goats affected with teat fistula, plain radiography did not give any diagnostic features. The visualization of fistula was not clear in positive as well as negative contrast radiography. The teat fistula in double contrast radiograph appeared as radio-opaque breach in radiolucent teat wall, the mucosa layer of teat appeared as radio-opaque lining (Fig. 11). In a goat present with pedunculated tumorous growth, when subjected for radiographic examinations revealed the growth more radio-opaque than udder and teats (Fig. 12) in plain, negative and double contrast radiography, while positive contrast radiography revealed no connectivity in teat canal.

The use of aqueous solution of Iohexol 350 as a positive contrast material in udder gave medium quality radiographs with even distribution without any systemic side effects. Plain, negative, positive and double contrast radiography of teat and udder were compared as an aid to locate lesions. Double contrast radiography gave the best results followed by negative contrast one followed by positive and no good differentiation in plain radiography, except in radio-opaque obstructions. Naeni and Gholami (1999) compared these types of radiography in healthy cows by using telebrix (380 mg/mL) and experienced that double contrast radiography was suitable to identify the lesions in udder and teat. Al-Maliki and Atiya (2020) used barium sulphate as a contrast media at different doses, which revealed 50 mL to be ideal to see the full structures of udder in cattle. Atiya (2009) also carried out positive contrast radiographic study of mammary glands

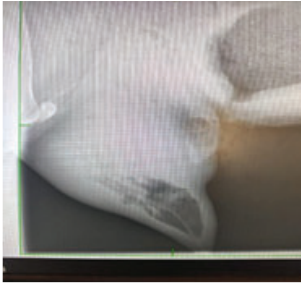
in small ruminants and observed that contrast agent above 30 mL caused disappearance of duct system.

Negative contrast medium, because of the clear solid contrast that it offers in visualising soft tissues and their abnormalities has more advantage over a positive contrast medium. The positive contrast medium lines the tissue surface, which become prominent against air filled teat cavity without obscuring any structure. Double contrast radiography was particularly suitable to trace ruptured, inverted mucous membranes, and any growth attached to mucosa. The best results were obtained with double contrast radiography.

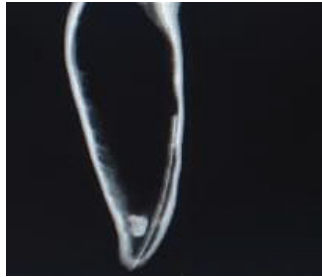#### Ultrasonography of Udder

In this study 36 goats were selected for ultrasonography comprised of healthy (n=6) goats and goats with various affections of udder and teat (n=30). Ultrasonography of udder with 5-10 MHz percutaneous rectal probe at 7.5 MHz in healthy goats (n=6) revealed skin as a hyperechoic line, and parenchyma as a homogenous structure of average echogenicity filled with anechoic content (milk) and presence of anechoic ducts (lactiferous ducts or blood vessels). The large lactiferous ducts were differentiated from the blood vessels as anechoic branches opened into the glandular sinus (Fig. 13). In the goats affected with mastitis (n=6), the ultrasonographic examinations revealed presence of hyperechoic threads in anechoic fluid in gland cistern with lack of clear visualization of the lactiferous ducts and thickened blood vessels in udder. There were clear demarcations between normal tissues as homogenous hypoechoic echotexture from the inflammatory tissue as heteroechoic echogenicity in udder affected with mastitis (Fig. 14). In a goat which was found to be positive for bacterial culture, that udder did not show any echostructural changes. The findings of the present study are in agreement with the reports of the Santos *et al.* (2015), Ragab *et al.* (2016) and Kotb *et al.* (2020) in mastitic cows and does. In contrary to present findings, Fasulkov *et al.* (2014) observed normal udder as homogenous hyperechoic structure, while the findings of the mastitic udders in goats were similar to our findings.

On ultrasonographic study fibrosed udders (n=6) appeared as homogeneous echotextures structures with hyperechogenicity (calcification) which separated remaining



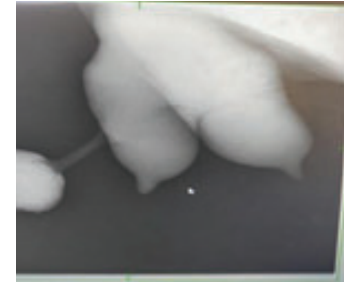**Fig. 9:** Negative contrast radiograph of teat spider



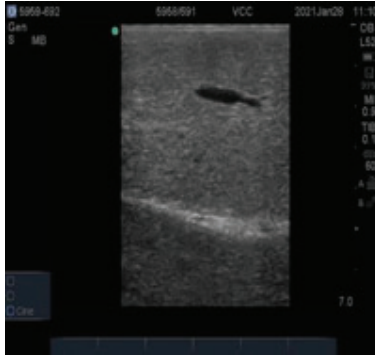**Fig. 10:** Double contrast radiography of growth in teat



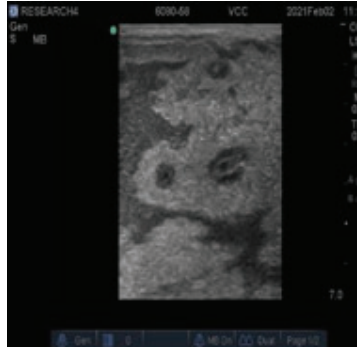
**Fig. 11:** Double contrast radiography of udder abscess



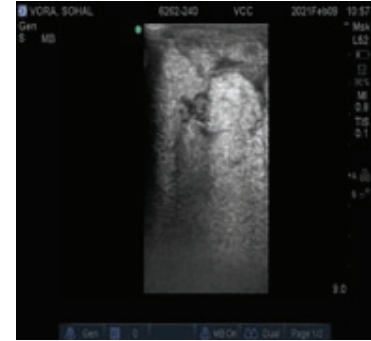
**Fig.12:** Plain radiography of tumour attached to teat



**Fig. 13:** USG of healthy udder



**Fig. 14:** USG of mastitic udder



**Fig. 15:** USG of fibrosed udder

parenchyma by thin anechoic margin (Fig. 15). These findings were in agreement with those of Jahangirbasha *et al.* (2016), whereas Kotb *et al.* (2020) reported hyperechoic fibrous tissues in udder parenchyma. In cases of gangrenous mastitis (n=4) the ultrasonographic examination revealed the mammary parenchyma as heterogenous in echotexture, with various free floating hyperechoic flocs, and perivascular oedema in blood vessels with increased diameter which appeared as double hyperechoic rings (vessel wall) with anechoic fluid (pus). There were clear demarcations between normal and gangrenous tissue due to difference in echotexture and echogenicity (Fig. 16).

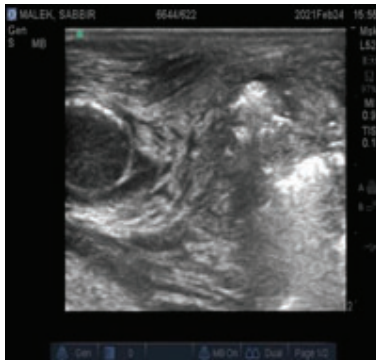
Ultrasonographic examinations in the goats with wounds on udder (n=2) revealed echo-structure as seen in normal healthy udder, except the presence of thick hyperechoic connective tissue lining around wounds. Screening of udder oedema (n=1) through ultrasonography revealed presence of anechoic fluid in subcutaneous tissues as well as intraparenchymal spaces of mammary tissue with heterotexture and hypoechogenic appearances of parenchyma with lose of normal demarcation of duct and gland cistern. There were no comparable references available in the literature regarding ultrasonographic examinations of gangrenous udder, wounds on udders and oedema of udder for the comparison.

In the goats affected with udder abscess (n=1), the abscess on ultrasonography appeared as a hypoechoic structure in small hyperechoic multiple round shape capsulated clusters, representing pus collections, surrounded by a hyperechoic membrane (capsule) (Fig. 17). Almost similar findings were

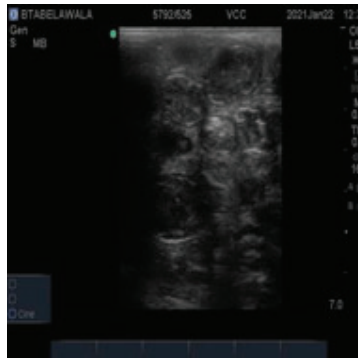reported by Ashwani Kumar *et al.* (2012) in goat with chronic suppurative mastitis and Fasulkov *et al.* (2014) in Bulgarian goats, Ragab *et al.* (2016) in cows and does, and Kotb *et al.* (2020) in goats. Supramammary lymph nodes were scanned in all animals by placing probe in vertical plane over the supramammary lymph nodes and scanned at caudal most of udder. They appeared as light hyperechoic round structures covered by hyperechoic membrane (capsule) (Fig. 18). The ultrasound of supramammary lymph node in mastitic udder showed enlarged hypoechoic parenchyma surrounded by thick capsule. There was no comparable reference available in the literature regarding ultrasonography of supramammary lymph nodes in goats.

### Ultrasonography of Teat

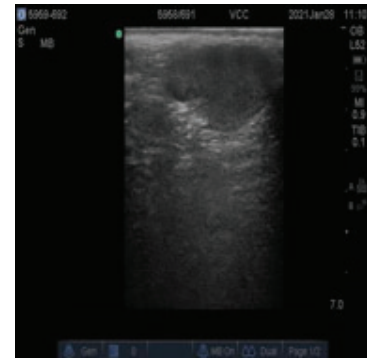Ultrasonography of teats was done in vertical plane for teat scan using water-bath technique, which showed better quality and resolution of images. The ultrasonography of teats of healthy goats revealed the whole teat cistern and gland cistern as filled with anechoic fluid. The demarcation between teat cistern and gland cistern was annular fold, which appeared as thin hyperechoic line. The teat orifice was visualized as a small anechoic formation at the teat's tip (Fig. 19). Almost similar observations were made by Fasulkov *et al.* (2013) and Franz *et al.* (2001) in healthy goats at 12 MHz frequency. Fasulkov (2012) also favoured the use of water-bath technique for the scanning of the teat in ruminants. The ultrasonographic examinations of teat obstructions (n=4) in goats revealed the sites of obstructions as 1 in proximal,



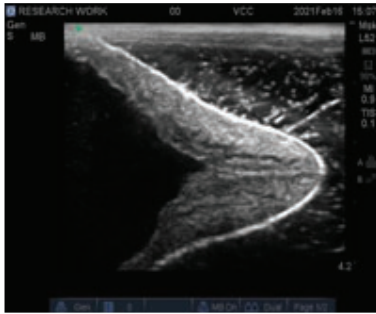
**Fig. 16:** USG of gangrenous mastitic udder



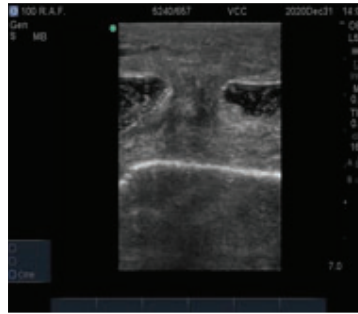**Fig. 17:** USG of udder abscess



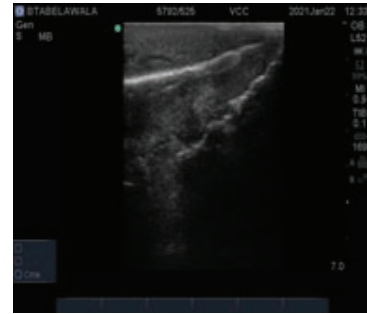
**Fig. 18:** USG of supramammary lymph node



**Fig. 19:** USG of normal teat



**Fig. 20:** USG of teat obstruction



**Fig. 21:** USG of teat fistula

2 in middle, 1 in distal of the teat. Complete obstruction appeared as limiting light hyperechoic membrane separating anechoic fluid (milk) (Fig. 20). In two goat membranous obstruction appeared as a hyperechoic band across the teat lumen, while in one case incomplete obstruction was seen as a anechoic track connecting two anechoic cavities. In other case there was obstruction due to hyperechoic round structure in teat cistern which was later found as large blood clot upon removal. In one case teat was blind without teat canal and teat cistern, only the echogenicity was uniform with teat wall seen as light hyperechoic. Ragab *et al.* (2016) reported presence of hyperechoic obstructive mass in teat canal. They also stated that the teat obstruction occurs at different levels, either at the base of teat due to chronic inflammation of the annular fold, at the teat canal due to milk calculi, polyps, and fibrosis of the teat canal or at the tip of the teat due to scratch and scab formation which may be complete or incomplete obstruction.

On ultrasonographic examinations of teats affected with teat fistula (n=3) an anechoic track was visualized as a breach in hyperechoic teat wall (Fig. 21). In the present study the fistula appeared anechoic. In contrary to the findings of the present study, Vasanth Kumar *et al.* (2019) reported a thick hypoechoic tubular structure in congenital teat fistula in cows. The variation of the appearance of the teat fistula might be due to time duration of occurrence with inflammation and thickening of the edges in fistula. The ultrasonographic examinations of teats with growth

(n=2), comprised of growth attached on caudal aspect of teat, which appeared as a large homogenous hypoechoic pouch with some anechoic fluid pockets. There was no continuity with teat cistern instead, there was hyperechoic folds of mucosa at the attachment site to teat. In a goat affected with teat laceration (n=1), the ultrasonography revealed loss of three layers differentiation around edges of laceration, despite teat wall appeared as a single homogenous hyperechoic around lacerated edge. There were no comparable references available regarding ultrasonographic examinations of teat lacerations.

## CONCLUSIONS

On the basis of findings of the present study it is concluded that the use of aqueous solution of Iohexol 350 as contrast media for udder and teat affections gives good quality radiographs with even distribution with no any systemic side effects. Double contrast radiography gives the best results followed by negative contrast one followed by positive, but no good differentiation in plan radiography, except in radio-opaque obstructions. Ultrasonography as an advanced tool at frequency 7.5 Hz with linear rectal probe helps in diagnosis of udder and teat in goats.

## ACKNOWLEDGEMENTS

Authors are grateful to the Dean of the College and University authorities of the Kamdhenu University, Anand for the facilities provided for this work.

## REFERENCES

- Abd-El-Hady, A.A.A. (2015). Clinical observations on some surgical udder and teat affections in cattle and buffaloes. *Scholars Journal of Agriculture and Veterinary Sciences*, 2(4A), 270-281.
- Alacam, E., Dine, D.A., Gijler, M., & Elma, E. (1990). Occurrence and radiological studies of different teat lesions in dairy cows. *Deutsche Tierärztliche Wochenschrift*, 97(12), 523-525.
- Al-Maliki, S.H., & Atyia, M.A. (2020). Macroscopical anatomy and radiographic study of the non-lactating udder of adult local Iraqi cows (*Bos taurus*). *Iraqi Journal of Veterinary Medicine*, 44(E0), 100-105.
- Ashwani Kumar, Mahajan, S.K., Singh, K., Sangwan, V., Chandra, M., Saini, N.S., & Anand, A. (2012). Unilateral mastectomy for the management of chronic suppurative mastitis in a goat. *Indian Journal of Small Ruminants*, 18(1), 148-151.
- Atyia, M.A. (2009). Anatomical, histological and radiological study of the mammary gland of small ruminants. *Basrah Journal of Veterinary Research*, 8(2), 10-22.
- Fasulkov, I.R. (2012). Ultrasonography of the mammary gland in ruminants: A review. *Bulgarian Journal of Veterinary Medicine*, 15(1), 1-12.
- Fasulkov, I., Georgiev, P., Wehrend, A., & Sandra Goericke-Peschb (2014). Ultrasonographic findings of pathological changes in the mammary gland in Bulgarian native goats. *Small Ruminant Research*, 120, 174-180.
- Fasulkov, I., Yotov, S., Atanasov, A., & Antonov, A. (2013). Evaluation of different techniques of teat ultrasonography in goats. *Journal of the Faculty of Veterinary Medicine Istanbul University*, 39(1), 33-39.
- Franz, S., Hofmann-Parisot, M., Baumgartner, W., Windischbauer, G., Suchy, A., & Bauder, B. (2001). Ultrasonography of the teat canal in cows and sheep. *The Veterinary Record*, 149, 109-112.
- Jahangirbasha, D., Shivaprakash, B.V., Dilipkumar, D., Bhagwantappa, B., Shivakumar, C.J., Sunil Naik, G., & Manzoor, S. (2016). Radical unilateral mastectomy as a salvage procedure in fibrosed gangrenous udder in a lactating goat. *International Journal of Applied and Pure Science and Agriculture*, 2(8), 135-143.
- Kotb, E.E.Z., Fadel, M., Abd Elfattah, O.A., Azab, A.M.S., & Leil, A.Z.A. (2020). Ultrasonography, histopathological udder alterations and bacteriological investigations for diagnosis of mastitic goats. *Journal of Applied Veterinary Sciences*, 5(2), 77-86.
- Naeini, T., & Gholami, A. (1999). Radiography of the bovine mammary gland. *Journal of Applied Animal Research*, 15(1), 53-56.
- Ragab, G.H., Seif, M.M., & Qutp, M.M. (2016). Ultrasonography of the mammary gland in ruminants. *Journal of Veterinary Medical Research*, 23(2), 125-132.
- Santos, V.J.C., Simplício, K., Sanchez, D., Coutinho, L., Teixeira, P., Barros, F., Almeida, V., Rodrigues, L., Bartlewski, P., Oliveira, M., Feliciano, M., & Vicente, W. (2015). B-mode and Doppler sonography of the mammary glands in dairy goats for mastitis diagnosis. *Reproduction in Domestic Animals*, 50, 251-255.
- Senthilkumar, S., Kannan, T.A., Gnanadevi, R., Ramesh, G., & Sumathi, D. (2020). Ultrasonographic anatomy of udder in indigenous Madras Red sheep. *The Haryana Veterinarian*, 59(2), 182-184.
- Singh, G., Vig, M.M., & Kumar, R. (1975). Contrast radiography in the diagnosis of teat affections. *Veterinary Radiology*, 16(1), 11-12.
- Singh, P., Singh, J., & Sharma, P.D. (2003). Surgical conditions of udder and teats in buffaloes. *Intas Polivet*, 4, 362-365.
- Vasanth Kumar, M.C., Adarsh Kumar, Farooq, U.B., Tyagi, S.P., & Gupta, A. (2019). Sonographic findings of congenital bovine teat and udder affections. *Indian Journal of Animal Research*, 53(4), 537-540.

