

Colonoscopic Examination, Histopathological Findings and Medical Management of Lymphocytic-Plasmacytic Colitis in a Dog

S. Vishnu Priya, G. Senthil Kumar, E. Venkatesakumar, K. Senthilvel

Ind J Vet Sci and Biotech (2023); 10.48165/ijvsbt.19.3.26

Colitis denotes inflammatory bowel disease affecting the large bowel, including the rectum which is the most common cause of chronic intestinal disease in dogs. The classification of inflammatory bowel disease (IBD) is determined by the presence of dominant type of inflammatory cells in the intestinal mucosa. Lymphocytic-plasmacytic enteritis is the most common histological form of idiopathic IBD in dogs (Yogeshpriya *et al.*, 2017). Nowadays, endoscopic examination is a diagnostic tool for identifying the etiology and management of gastrointestinal disorders in dogs. Colonoscopy is performed to determine the occurrence of disorders or abnormalities in the large intestine (Cartwright *et al.*, 2016). Colonoscopic examination with endoscopically guided mucosal biopsy is the basis for confirming chronic inflammatory diseases and to determine the extent of disease (Rychlik *et al.*, 2007; Rychlik and Kaczmar, 2020). Endoscopy also helps to estimate the efficiency of the treatment strategy applied. This study sets out a colonoscopic diagnosis, histopathological findings and medical management of lymphocytic-plasmacytic colitis in a dog.

CASE HISTORY, OBSERVATIONS AND DIAGNOSIS

A seven years old intact male German Shepherd was presented to Veterinary Clinical Complex, Veterinary College and Research Institute, Namakkal, Tamilnadu, with the history of hematochezia and mucus in faeces (Fig. 1) for the past one week, tenesmus and frequent voiding of small volume of faeces. On clinical examination, the animal appeared active with a body temperature of 38.2°C, heart rate of 132 per min, respiratory rate of 27 per min, capillary refilling time of less than 2 sec and palpable popliteal lymph nodes. However, on abdominal palpation and digital rectal examination, pain evinced and hematochezia noticed. Hemato-biochemical analysis revealed slight lymphocytopenia, hypoproteinemia and hypoalbuminemia (Table 1). Faecal samples examination was negative for ova or oocyst of parasite and no blood parasite on peripheral blood smear examination. Abdominal ultrasonography showed normal intestinal mucosa.

Due to the fact that the predominant sign was large intestinal diarrhea, Colonoscopy was performed by

Department of Veterinary Clinical Medicine, Veterinary College and Research Institute, Namakkal - 637 002, TANUVAS, Tamilnadu, India

Corresponding Author: G. Senthil Kumar, Department of Veterinary Clinical Medicine, Veterinary College and Research Institute, Namakkal - 637 002, TANUVAS, Tamilnadu, Indiagskmvsc@gmail.com

How to cite this article: Priya, V. S., Senthilkumar, G., Venkatesakumar, E., & Senthilvel, K. (2023). Colonoscopic Examination, Histopathological Findings and Medical Management of Lymphocytic-Plasmacytic Colitis in a Dog. *Ind J Vet Sci and Biotech*. 19(3), 108-110.

Source of support: Nil

Conflict of interest: None.

Submitted: 27/01/2023 **Accepted:** 02/03/2023 **Published:** 10/05/2023

placing the animal in left lateral recumbency with Flexible Gastrointestinal video fiberscope (Olympus GIF-V70). The dog was administered with PEGLEC® - oral gastrointestinal lavage solution @ 80 mL/kg b.wt. in 2 equally divided doses at 4-6 h interval in the previous day and phosphate enema was given just before colonoscopic procedure. During the procedure, the entire colon was visualized and an endoscopic guided biopsy was collected from the colon mucosa for histopathological examination.



Fig. 1: Hematochezia and mucus coated stool

Colitis and chronic enteritis have been diagnosed through the exclusion of systemic, parasitic, infectious, pancreatic and structural cause of chronic diarrhea, and by proving excessive counts of lymphocytes and plasma cells in the endoscopic guided intestinal biopsy (Rychlik *et al.*, 2007). Endoscopic examination of colon showed that mucosa was

hyperaemic with mucosal irregularity, friability, erosion, ulceration, non-distensible colon wall, loss of visualization of submucosal vessels, narrowing of lumen, extensive ulceration with hyperaemic mucosa throughout the descending colon (Fig. 2, 3). Transverse and ascending colon appeared apparently normal with no obvious macroscopic lesions. Hence the present case was tentatively diagnosed as inflammatory bowel disease. In the diagnosis of IBD, endoscopic guided biopsy from colonic mucosa in the ulcerated site was collected, fixed in 10% formalin, paraffin-embedded and subjected to histopathological examination.

Table 1: Hemato-biochemical values

Parameters	Pre-treatment	Post-treatment	Reference range
Haematology			
Hemoglobin (g/dL)	13.5	12.3	12-19
Packed cell volume (%)	45.7	38	37-57
Total erythrocyte count (x 10 ⁶ /μL)	6.37	5.9	5.0-9.0
Total leucocyte count (x 10 ³ /μL)	12.82	13.27	5.0-15.0
Neutrophils (%)	75	73.2	60-75
Lymphocytes%	16.5	19.7	18-21
Monocytes (%)	8.5	7.1	2-10
Eosinophils (%)	0	0	0-9
Basophils (%)	0	0	0-1
Platelet count (x10 ³ /μL)	506	565	1.6-5.1
Serum biochemistry			
Total protein(g/ dL)	5.1	6.7	5.4-7.1
Albumin(g/ dL)	1.6	2.9	2.3-3.3
Alanine transaminase(U/L)	30	43	10-109
Alkaline phosphatase (U/L)	14	62	20-156
Blood urea nitrogen(mg/ dL)	7.0	10	8.0-28.0
Creatinine(mg/ dL)	1.3	1.2	0.4-1.4
Phosphorus(mg/ dL)	4.8	4.3	2.6-5.3
Potassium (mEq/L)	3.6	3.4	3.9-5.1

Collected biopsy specimens can be used to determine degree of inflammation, differentiate inflammatory and neoplastic lesions (Rychlik and Kaczmar, 2020). Biopsy should

be taken for histopathological examination regardless of the presence or absence of macroscopic changes (Fefferman and Farrell, 2005). Histopathological findings in the present case revealed absence of superficial epithelial layer, degeneration of crypt epithelial cells with fibrous tissue and abundant lymphocytes and plasmacytes infiltration in the lamina propria (Fig. 4). Based on the history, clinical signs, colonoscopic observations and histopathological examination, the case was confirmed as lymphocytic-plasmacytic colitis.

TREATMENT AND DISCUSSION

The dog was treated with oral Mesalazine @ 20 mg/kg b.wt. twice daily and oral prednisolone @ 1 mg/kg b.wt. twice daily for 14 days. The animal had uneventful recovery after 4 weeks. Malewska *et al.* (2011) reported the use of Mesalazine @ 12.5 mg/kg b.wt. BID for 4 to 6 weeks for the treatment of colitis in dog. Churcher and Watson (1997) described one severely affected dog that responded well clinically to prednisolone, sulphasalazine and dietary modification.

There was improvement in the defecation and appetite. On clinical examination, all the vital parameters were normal. Hemato-biochemical parameters were normal with improvement in the total protein and albumin. After 2 weeks of completion of treatment, a colonoscopy revealed pink, smooth, glistening mucosa, visualization of submucosal vessels without any mucosal lesion (Fig. 5, 6). Histopathological examination of endoscopic guided colon mucosal biopsy revealed mild degeneration of mucosal epithelium, crypts epithelial cell hyperplasia with and very few mononuclear cell infiltration in the lamina propria (Fig. 7). The improvement in this case is manifested by decrease in number of infiltrating cells in the colonic lamina propria.

Clinical signs of IBD may vary widely and their occurrence is dependent on the location and intensity of cellular infiltration. A very rare case has been documented so far regarding inflammatory bowel disease of large intestinal origin.

From the present case findings, it may be concluded that the negative radiographic and ultrasonographic finding makes endoscopy the basic examination technique

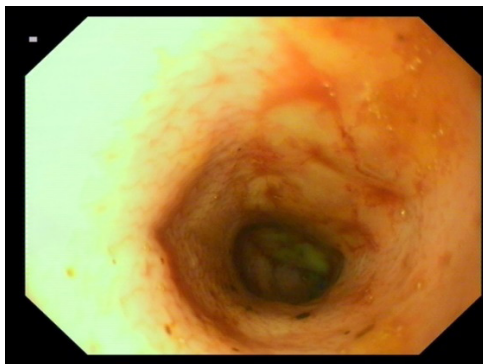


Fig.2: Mucosal irregularity, hyperaemic, erosion, ulceration, non-distensible colon wall, loss of visualization of submucosal vessels and narrowed lumen

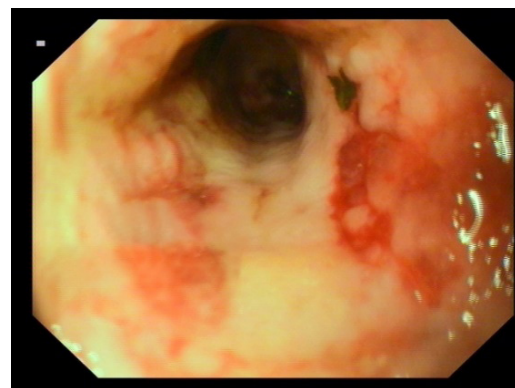


Fig.3: Extensive ulceration and hyperaemic throughout the descending colon

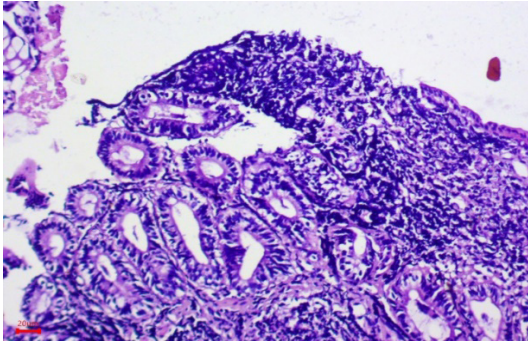


Fig. 4: Absence of superficial epithelial layer, degeneration of crypt epithelial cells with fibrous tissue and abundant lymphocytes plasmacytes infiltration in the lamina propria

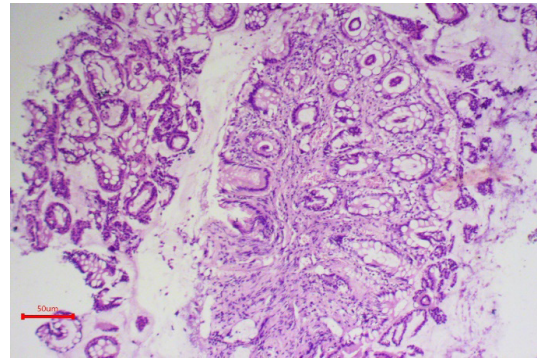


Fig. 7: Mild degeneration of mucosal epithelium, crypts epithelial cell hyperplasia with and very few mononuclear cell infiltration in the lamina propria

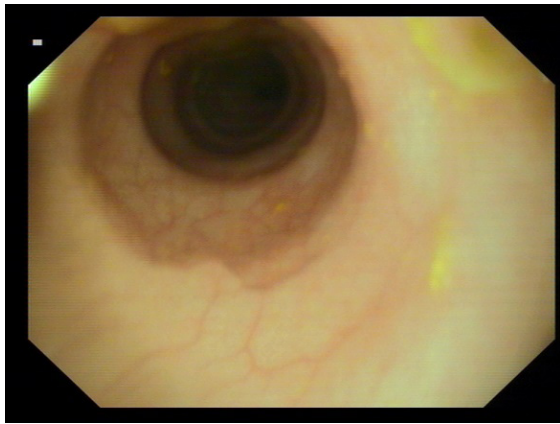


Fig. 5: Tunnel view of colon - normal appearance of colonic mucosa without ulcer

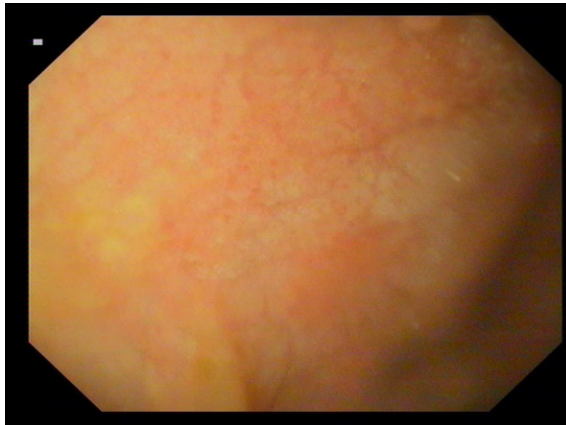


Fig. 6: mucosa - pink, smooth, glistening with visualization of submucosal vessels

for diagnosis of IBD in dogs. In this study, the therapy with mesalazine and prednisolone helped in early recovery of lymphocytic-plasmacytic colitis in dog.

ACKNOWLEDGEMENT

The authors are thankful to The Dean, Veterinary College and Research Institute, Namakkal, TANUVAS, Tamilnadu, for providing necessity facilities in completion of this study.

REFERENCES

- Cartwright, J.A., Breheny, C., Major, A.C., Hill, T.L., & Gow, A.G. (2016). Imaging diagnosis - a case of spontaneous hepatic portal vein gas in an 11-month-old west highland white terrier. *Veterinary Radiology & Ultrasound*, 57(5), 54-57.
- Churcher, R.K., & Watson, A.D.J. (1997). Canine histiocytic ulcerative colitis. *Australia Veterinary Journal*, 75, 710-713.
- Fefferman, D.S., & Farrell, R.J. (2005). Endoscopy in inflammatory bowel disease: Retrospective analysis of diagnosis and outcome in 80 cases (1995-2002). *Journal of Small Animal Practice*, 45, 336-342.
- Malewska, K., Rychlik, A., Nieradka, R., & Kander, M. (2011). Treatment of inflammatory bowel disease (IBD) in dogs and cats. *Polish Journal of Veterinary Sciences*, 14(1), 165-171.
- Rychlik, A., Nieradka, R., Kander, M., Depta, A., Nowicki, M., & Sarti, K. (2007). Usefulness of endoscopic examination for the diagnosis of inflammatory bowel disease in the dog. *Polish Journal of Veterinary Sciences*, 10, 113-118.
- Rychlik, A., & Kaczmar, K. (2020). Endoscopic biopsies and histopathological findings in diagnosing chronic gastrointestinal disorders in dogs and cats. *Veterinary Medicine International*, Vol?, 1-8.
- Yogeshpriya, S., Veeraselvam, M., Krishnakumar, S., Arulkumar, T., Jayalakshmi, K., Saravanan, M., Ranjithkumar, M., Sivakumar, M., & Selvaraj, P. (2017). Technical review on inflammatory bowel disease in dogs and cats. *International Journal of Science, Environment and Technology*, 6(3), 1833-1842.

