

Colopexy in Cats with Recurrent Rectal Prolapse: A Case Series

Shahid Hussain Dar^{1*}, Mursaleen Bhat², Raja Ahmad Aijaz¹, Mudasir Bashir Gugjoo¹, Amatul Muhee¹

Ind J Vet Sci and Biotech (2026): 10.48165/ijvsbt.22.3.38

Rectal prolapse is a frequently encountered condition in small animal practice and is characterized by protrusion of the rectal mucosa or full-thickness rectal wall through the anal opening. In cats, rectal prolapse is commonly associated with persistent tenesmus secondary to gastrointestinal disorders such as parasitism, diarrhea, constipation, colitis, or urinary tract diseases (Birchard and Sherding, 2016; Fossum, 2019).

Acute cases of rectal prolapse may respond favourably to conservative management, including manual reduction followed by purse-string suturing and treatment of the underlying cause. However, recurrent rectal prolapse is often challenging to manage and may result in edema, ulceration, ischemia, and necrosis of the rectal tissue if left untreated (Smeak, 2006; Tobias and Johnston, 2012). In such cases, a more definitive surgical approach is required. Colopexy is a surgical technique that involves fixation of the colon to the abdominal wall to prevent caudal displacement and recurrence of prolapse. The procedure has been reported to be effective in both dogs and cats with recurrent rectal prolapse (Orsher, 1995; Ellison and Lewis, 2018). The present case series describes the clinical presentation, surgical management, and outcome of colopexy in cats with recurrent rectal prolapse.

CASE HISTORY AND OBSERVATIONS

Ten cats presented to the Division of Veterinary Clinical Complex, Faculty of Veterinary Sciences and Animal Husbandry, SKUAST-K (India), were included in the study. All cats had a history of recurrent rectal prolapse, with recurrence occurring at least three times despite prior treatment by manual reduction, purse-string suturing, and deworming (Fig. 1). The cats comprised six males and four females, with age ranging from three months to two years. Age distribution included cats aged three months (n=2), four months (n=2), six months (n=3), seven months (n=1), eight months (n=1), twelve months (n=1), and two years (n=1). Based on clinical history and observations, it was decided to go for colopexy following standard surgery.

¹Division of Veterinary Clinical Complex, Faculty of Veterinary Sciences & Animal Husbandry, SKUAST-K, Shuhama, Srinagar-190006, J&K, India

²Division of Veterinary Surgery & Radiology, Faculty of Veterinary Sciences & Animal Husbandry, SKUAST-K, Shuhama, Srinagar-190006, J&K, India

Corresponding Author: Dr. Shahid Hussain Dar, Associate Professor, Division of Veterinary Clinical Complex, Faculty of Veterinary Sciences & Animal Husbandry, SKUAST-K, Shuhama, Srinagar-190006, J&K, India. e-mail: shahidvsr@gmail.com

How to cite this article: Dar, S. H., Bhat, M., Aijaz, R. A., Gugjoo, M. B., & Muhee, M. (2026). Colopexy in Cats with Recurrent Rectal Prolapse: A Case Series. *Ind J Vet Sci and Biotech*, 22(3), 187-189.

Source of support: Nil

Conflict of interest: None

Submitted 11/01/2026 **Accepted** 23/02/2026 **Published** 10/05/2026

SURGICAL TREATMENT AND DISCUSSION

The cats were premedicated with xylazine (0.5 mg/kg body weight, intramuscularly) and ketamine (8 mg/kg body weight, intramuscularly). General anaesthesia was induced with propofol (4 mg/kg body weight, intravenously, to effect) and maintained using isoflurane inhalation anaesthesia delivered through a Bain's breathing system with an oxygen flow rate of 200 mL/min.

Following routine aseptic preparation, a ventral midline celiotomy was performed. The descending colon was identified, and colopexy was achieved by suturing the antimesenteric border of the colon to the left abdominal wall using polygalactin 910 (3-0) in a simple interrupted pattern (Fig. 2A, 2B). Care was taken to avoid excessive tension and to ensure proper tissue apposition. The abdominal wall and skin were closed routinely (Fig. 3). Postoperatively, cats were monitored closely for recovery and were provided appropriate analgesia and supportive care. Owners were advised regarding postoperative wound care and follow-up. Colopexy was successfully performed in all ten cats without any intraoperative complications. The surgical procedure provided effective stabilization of the colon in all cases. Postoperative recovery was uneventful, and all cats resumed normal defecation within a few days following surgery. During a follow-up period of three years, none of the cats

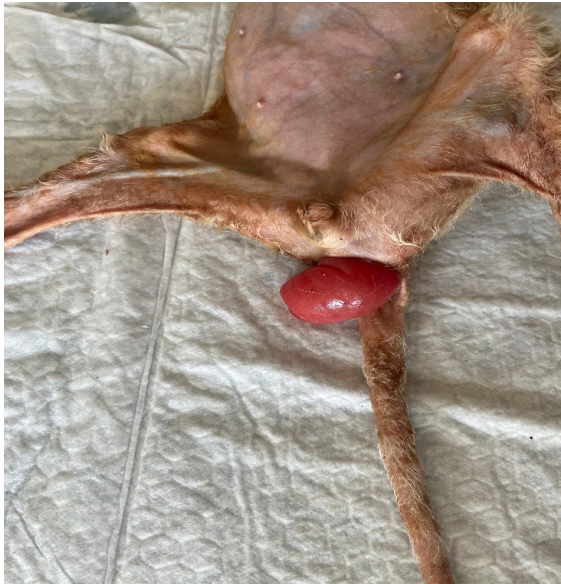

Fig. 1: Recurrent rectal prolapse.

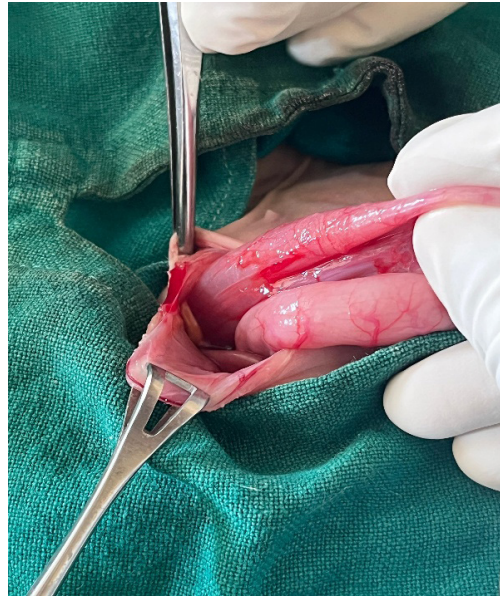

Fig. 2A: Ventral midline celiotomy and exteriorization of the descending colon;

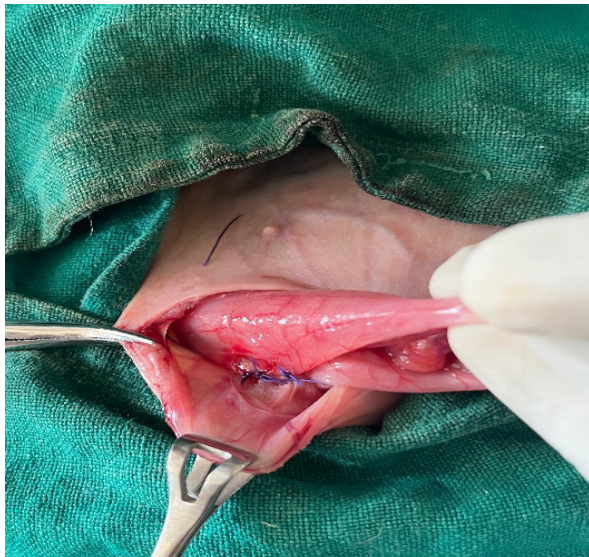


Fig. 2B: Suturing of the antimesenteric border of the colon to the left abdominal wall using polyglactin 910 (3-0)

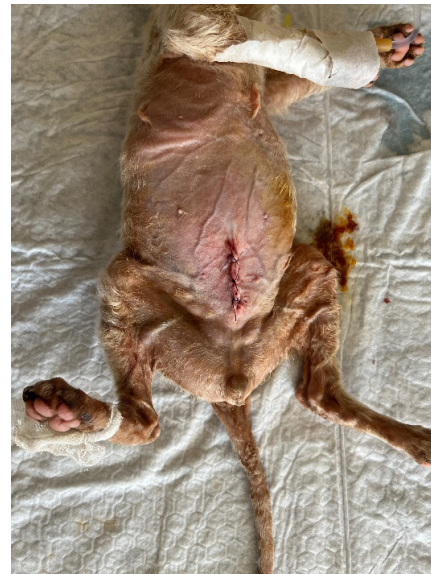

Fig. 3: Postoperative appearance of the cat following colopecty showing normal perineal anatomy and absence of rectal prolapse during follow-up

exhibited recurrence of rectal prolapse. No postoperative complications such as wound infection, dehiscence, constipation, or tenesmus were observed.

Recurrent rectal prolapse represents a significant therapeutic challenge in feline practice, particularly when conservative measures fail to provide lasting resolution. While manual reduction and purse-string suturing are effective in acute cases, repeated recurrence necessitates a more definitive surgical intervention (Birchard and Sherding, 2016; Fossum, 2019). Colopecty prevents caudal displacement of the colon by anchoring it to the abdominal wall, thereby

reducing the likelihood of recurrence during episodes of straining. Previous reports have documented high success rates following colopecty in dogs and cats with recurrent rectal prolapse (Orsher, 1995; Monnet, 2013). The absence of recurrence in all cases during the follow-up period in the present study further supports the efficacy of this procedure.

The anaesthetic and surgical protocols employed in the present case series provided adequate muscle relaxation, analgesia, and smooth recovery, consistent with recommended approaches for feline abdominal surgery (Radlinsky, 2014; Grimm *et al.*, 2015). Early surgical

intervention following repeated recurrence may help prevent complications such as rectal necrosis, chronic tenesmus, and compromised animal welfare (Ellison and Lewis, 2018).

In brief, colopexy is a safe, effective, and reliable surgical option for the management of recurrent rectal prolapse in cats when conservative treatment fails. The procedure resulted in complete resolution of clinical signs and absence of recurrence during the follow-up period in all cases. Early consideration of colopexy in recurrent cases may reduce morbidity and improve long-term outcomes.

ACKNOWLEDGEMENT

We thank the Dean, Faculty of Veterinary Sciences & Animal Husbandry, SKUAST-K, Shuhama, Srinagar, J&K for the facilities provided.

REFERENCES

- Birchard, S.J., & Sherding, R.G. (2016). *Saunders Manual of Small Animal Practice*, 3rd edn., Elsevier, St. Louis.
- Ellison, G.W., & Lewis, D.D. (2018). Rectum and anus. In: Tobias, K.M. and Johnston, S.A. (eds.), *Veterinary Surgery: Small Animal*. 2nd edn., Elsevier, St. Louis, pp. 1517-1534.
- Fossum, T.W. (2019). *Small Animal Surgery*, 5th edn., Elsevier, St. Louis.
- Grimm, K.A., Lamont, L.A., Tranquilli, W.J., Greene, S.A., & Robertson, S.A. (2015). *Veterinary Anaesthesia and Analgesia*: 5th edn of Lumb & Jones. Wiley-Blackwell, Ames.
- Monnet, E. (2013). Colopexy techniques in small animals. *Veterinary Surgery*, 42(5), 566-571.
- Orsher, R.J. (1995). Surgical correction of rectal prolapse in dogs and cats. *Compendium of Continuing Education Practice in Veterinary*, 17, 301-307.
- Radlinsky, M.G. (2014). Surgery of the colon. *Veterinary Clinics: North American Small Animal Practice*, 44(1), 83-99.
- Smeak, D.D. (2006). Management of rectal prolapse in small animals. *Veterinary Clinics: North American Small Animal Practice*, 36(1), 171-180.
- Tobias, K.M., & Johnston, S.A. (2012). *Veterinary Surgery: Small Animal*. Vol. 2. Elsevier, St Louis.