

Traumatic Diaphragmatic Hernia: Diagnosis and Surgical Treatment in a Five-Month-Old Pup

Amit Kumar^{1*}, Inder Pal Singh¹, Ansu Kumari², Anavil Bhardwaz³, Gitesh Saini³

Ind J Vet Sci and Biotech (2025): 10.48165/ijvsbt.21.6.38

The diaphragm serves as a muscular partition between thoracic and abdominal cavities that extends across the base of the thorax. The diaphragm plays a vital role during inspiration as its contraction causes the lungs to expand and fill with air. A diaphragmatic hernia (DH) is a condition in which rupture of the diaphragm allows abdominal organs to migrate into the pleural cavity. In companion animals, blunt trauma to the abdomen due to motor vehicle accidents is the common cause of traumatic DH (Hoddinott, 2013). Several other theories include an abrupt upsurge in the intraabdominal pressure following a powerful blow and failure of the glottis to remain closed, allowing the stabilizing effect of the air-filled lungs to be lost acutely (Hoddinott, 2013) or establishment of an acute and severe pressure gradient between the pleural and peritoneal cavities (Boudrieau, 1993) results in DH. The actual rupture or tear(s) occurs in the diaphragm which is least protected by the viscera at the time of injury.

The liver is more frequently involved in herniation. Within the thoracic cavity, left-sided hernia involves the displacement of the stomach, spleen, and small intestine, whereas herniation of the liver, pancreas, and small intestine occurs in right-sided rupture (Sullivan and Reid, 1990). The signs of hernia vary in concordance with herniated organ in the thorax and in case of sudden injury, respiratory distress is the predominant observed sign in dogs (Ozer *et al.*, 2007; Park and Lee, 2018; Yaygingul *et al.*, 2019; Zamirbekova *et al.*, 2020). If the stomach is trapped in the hernia, it may bloat and the animal's condition may worsen rapidly. In milder, long-term cases, general signs such as weight loss may be more noticeable than respiratory signs. Muffled heart and lung sounds are detected on auscultation of the thorax. A definitive diagnosis is most frequently made from radiography, which reveals changes in the shape of the diaphragm, loss of the diaphragmatic line, masking of cardiac shadow, and presence of the abdominal organs in the thoracic cavity (Sullivan and Lee, 1989). Pleural effusion may be present in 20% to 25% of cases and is usually associated with chronic liver herniation. Surgical repair of the hernia is the only treatment. If other trauma is present, the animal's condition is usually stabilized before surgical correction of the hernia. This paper reports diagnosis and an attempt of

¹Department of Veterinary Surgery and Radiology, College of Veterinary Science, Rampura Phul-151103, Bathinda, GADVASU, Punjab, India,

²Department of Veterinary Medicine, College of Veterinary Science, Rampura Phul-151103, Bathinda, GADVASU, Punjab, India

³Department of Veterinary Gynaecology and Obstetrics, College of Veterinary Science, Rampura Phul-151103, Bathinda, GADVASU, Punjab, India

Corresponding Author: Dr. Amit Kumar, Assistant Professor, Department of Veterinary Surgery and Radiology, College of Veterinary Science, Rampura Phul-151103, Bathinda, GADVASU, Punjab, India. e-mail: amitdharatterwal@gmail.com

How to cite this article: Kumar, A., Singh, I. P., Kumari, A., Bhardwaz, A., & Saini, G. (2025). Traumatic Diaphragmatic Hernia: Diagnosis and Surgical Treatment in a Five-Month-Old Pup. *Ind J Vet Sci and Biotech*, 21(6), 189-191.

Source of support: Nil

Conflict of interest: None

Submitted 09/05/2025 **Accepted** 28/05/2025 **Published** 10/11/2025

surgical repair of traumatic diaphragmatic hernia in a five-month-old pup.

CASE HISTORY AND OBSERVATIONS

A five-month-old non-descript female pup (Fig. 1A) was brought to the Veterinary Clinical Complex, Rampura Phul, Bathinda (India) with a history of an automobile accident past three days followed by severe respiratory distress with irregular respiration. Clinical examination revealed pale mucus membrane and tachypnea while temperature, pulse, and heart rate were within normal range. On auscultation, muffling sounds were heard from both the heart and lungs, and on palpation abdominal organs could not be detected within the abdominal cavity. Based on history and clinical signs, pup was tentatively diagnosed with diaphragmatic hernia.

To confirm the diagnosis, radiographs of the thorax and abdomen were taken in the right lateral recumbency and ventrodorsal (VD) position. Evident radiographic findings were the presence of abdominal organs in the thoracic cavity (liver, stomach, and small intestine; Fig. 1B), and the absence of a diaphragmatic line (Fig. 1C), silhouetted appearance of the heart (Fig. 1C), caudal and dorsal displacement of the

lungs (Fig. 1C). The pup also underwent ultrasonographic evaluation which further supported the radiographic findings as the liver was not followed by a diaphragmatic line and displacement of the organs was observed. Haematological examination exhibited normocytic hypochromic anaemia, relative lymphocytosis, platelet activation with normal count, and a decrease in packed cell volume and total erythrocyte count. The only treatment for diaphragmatic hernias is surgical repair (Park and Lee, 2018; Yaygingul *et al.*, 2019). Hence, soon after the definitive diagnosis, it was decided to operate the pup for surgical repair of DH.

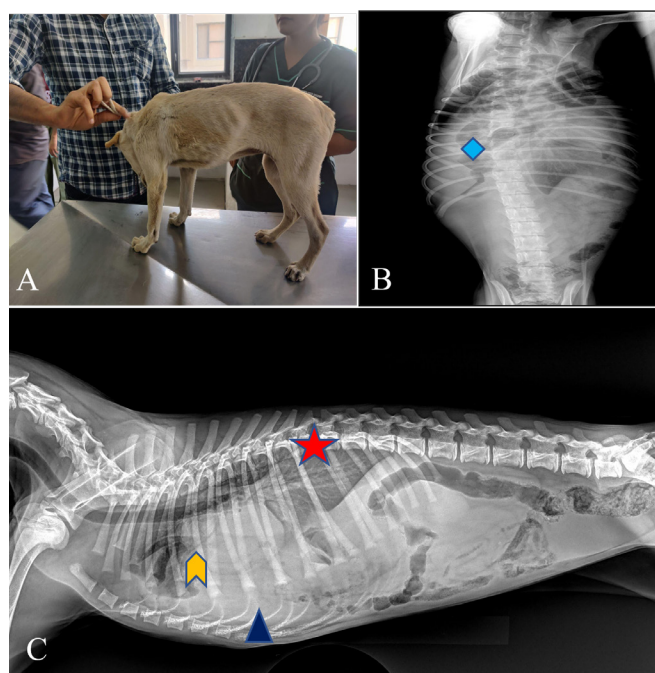


Fig. 1: (A) Five-month-old non-descript DH affected pup. (B) Ventrodorsal radiograph showing intestinal loops in the thorax. (C) A red star indicates dorsal upliftment of the lungs, blue triangle indicates herniation of the liver in the thorax and yellow arrow indicates upliftment of heart.

SURGICAL TREATMENT AND DISCUSSION

Before surgery, the pup was administered with Meloxicam (@ 0.2 mg/kg b.wt., i/m) an Intacef tazo (ceftriaxone & tazobactam @ 20 mg/kg, b.wt., i/v). Pre-anaesthetic medication included Atropine @ 0.04 mg/kg b.wt. and Butorphanol @ 0.2 mg/kg b.wt., via intramuscular route. After induction with Propofol (4 mg/kg b.wt., i/v), the patient was intubated with an endotracheal tube and maintained with isoflurane anaesthesia. Lactated Ringer's solution was administered (10 mL/kg/h, i/v) throughout anaesthesia. The dog was moved to the operating room, positioned in dorsal recumbency, and connected to an anaesthetic machine. The initial vaporizer setting was 2% isoflurane. After aseptic surgical site preparation, a skin incision of approximately 6-8 cm was made along the midline of the abdomen posterior to the xiphoid prominence, and the subcutaneous tissue was separated to expose the abdominal cavity.

Part of the liver and intestine could be seen, and an abnormal intestinal course was seen running down the intestine. Further exploration revealed that part of the small intestine, liver, and spleen had entered the thoracic cavity, and the whole diaphragm was ruptured on the ventral aspect of the abdomen. First, the intestine that had entered the thoracic cavity was slowly removed and retracted outside the body, followed by the move out of the liver and spleen (Fig. 2A, 2B). A significant amount of serosanguineous fluid was present in the thoracic cavity, which was absorbed with the help of gauze. The thoracic and abdominal organs were examined for ischemia or other injuries. Each organ was found intact. Herniated organs after retraction from the thoracic cavity were placed back into the abdomen (Fig. 2C). The ruptured diaphragm was sutured with a simple continuous suture pattern using Vicryl no.1 (polyglactin 910). The intestine and liver were reset followed by abdominal muscles suturing with an interlocking pattern using Vicryl No.1. (Polygalactin 910) and skin incision was closed via a simple interrupted pattern using Nylon No.1 (Polyamide) (Fig. 2D). After surgical repair in a postoperative radiograph, the diaphragmatic line was found intact, heart, lungs and abdominal organs were present at normal positions.

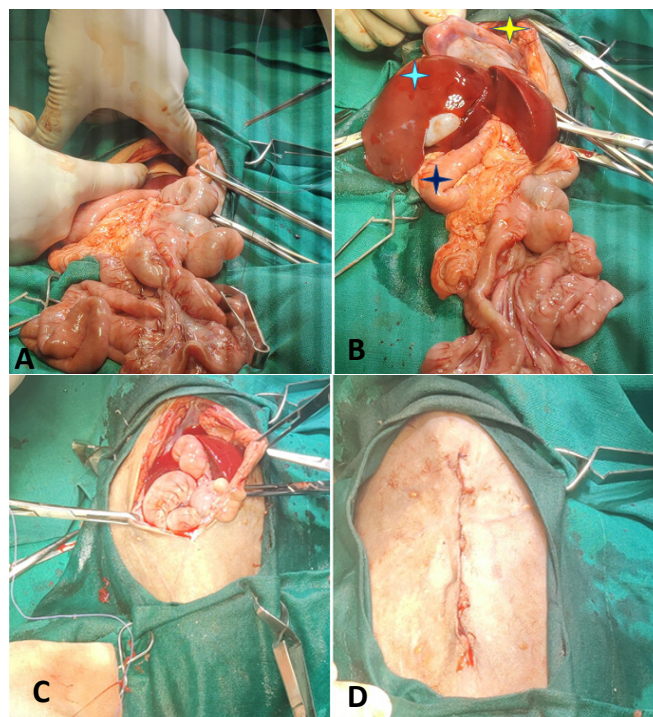


Fig. 2: Intraoperative findings. (A) Liver and intestinal herniation into the thorax. (B) The organ indicated by the yellow point is the hernia, the sky blue point is the liver, whereas the deep blue point is the intestine. (C) All the abdominal organs are placed back into the thorax. (D) Routine muscle & skin suturing.

During post-operative period medication with injections of ceftriaxone and tazobactam @ 20 mg/kg intramuscularly once a day, Meloxicam @ 0.3 mg/kg intramuscularly twice a day, multivitamin (Mecovet) @ 0.5 mL intramuscularly once a

day for five days and hematinic syrup (a RBC pet syrup) @ one teaspoon twice a day for 15 days was advised to administer. Daily thrice a day antiseptic dressing of surgical site with liquid betadine and application of E-collar were recommended along with removal of sutures on 14th day post-surgery. However, the animal collapsed after a few h of surgical repair.

The present case report describes a case of a diaphragmatic hernia in a pup after an accident with a motor vehicle. Diaphragmatic hernia is most commonly seen in the pleural and refers to the protrusion of abdominal visceral organs into the thoracic cavity through a natural or traumatic diaphragmatic vent (O'Byrne *et al.*, 2021). Motor vehicle accidents or blunt abdominal traumas resulting in increased abdominal pressure are the most common causes of traumatic DHs (Hoddinott, 2013). The location of diaphragmatic rupture is related to both the location of the external impact and the position of the dog at the time of trauma (O'Byrne *et al.*, 2021). The clinical symptoms of traumatic DH are mainly related to the displacement of internal organs and are seen in the lungs, heart, and gastrointestinal tract. Herniation of the organs depends on the location of diaphragmatic rupture, and it varies with the organs involved. Diagnosis of DH is done with the help of radiography and ultrasonography (Campanile *et al.*, 2024).

Surgical intervention is required in all cases of traumatic DH. Most postsurgical mortalities happen within the first 24 h after intervention regardless of the nature of herniation owing to haemothorax and pneumothorax (Garson *et al.*, 1980). The small size of the pup and sudden and severe rise in the intrabdominal pressure led to the diaphragmatic rupture. Tentative diagnosis, based on the history and clinical signs, was confirmed through conventional radiography and ultrasonography (Ban *et al.*, 2019; Zhang *et al.*, 2020). Due to displacement of the cardia and dorsal upliftment of the lungs along with herniation of the liver, spleen, and small intestine in the thorax, the pup presented with signs of severe respiratory distress. Anaemia developed as a consequence of internal haemorrhage. Soon after the diagnosis was made diaphragm was repaired by diaphragmatic herniorrhaphy via laparotomy, thoracotomy, combined thoracic-abdominal, and single paracostal approach. Haemothorax, fragile liver along with multiple abdominal adhesions attributed to the grave prognosis. Postoperatively pup was managed with broad-spectrum antibiotics, anti-inflammatory agents, haematinics, and multivitamin injections. However, due to the majority of the diaphragmatic rupture and other complications pup collapsed after a few hours of post-surgical intervention.

This study provides insight into the etiology, diagnosis, and treatment of traumatic diaphragmatic hernia in pups.

ACKNOWLEDGEMENT

Authors are thankful to the Dean, College of Veterinary Science, Rampura Phul, GADVASU for providing all the facilities.

REFERENCES

- Ban, C.P., Cheng, R., Zhang, X.Q., Huang, Y.Q., Li, X.M., & Liang, G.Q. (2019). Diagnosis and treatment of a case of diaphragmatic hernia in a dog. *Journal of Anhui Agricultural Sciences*, 47, 98-100
- Boudrieau, R.J. (1993). Pathophysiology of traumatic diaphragmatic hernia. In: M. J. Bojrab (Ed.). *Disease Mechanisms In Small Animal Surgery*. 2nd edn., Lea & Febiger, pp. 103-108.
- Campanile, D., Cafaro, M., Paci, S., Panarese, M., Sparapano, G., Masi, M., & De Simone, A. (2024). Evidence of pneumopericardium after elective ovarioectomy in a peritoneopericardial diaphragmatic hernia-affected dog: a case report. *Animals*, 14(4), 633.
- Garson, H.L., Dodman, N.H., & Baker, G.J. (1980). Diaphragmatic hernia: Analysis of fifty-six cases in dogs and cats. *Journal of Small Animal Practice*, 21, 469-481.
- Hoddinott, K. (2013). Traumatic diaphragmatic hernia in a 5-month-old Boxer dog. *Canadian Veterinary Journal*, 54, 507-509.
- O'Byrne, K.L., Smalle, T., & Ryan, S.D. (2021). Repair of a delayed, traumatic dorsal diaphragmatic hernia using a single paracostal approach in a dog. *New Zealand Veterinary Journal*, 70, 55-62.
- Ozer, K., Guzel, O., Devecioglu, Y., & Aksoy, O. (2007). Diaphragmatic hernia in cats: 44 cases. *Medycyna Weterynaryjna*, 63(12), 1564-1567.
- Park, S., & Lee, J.M. (2018). Diaphragmatic hernia in a two-month-old cat. *Journal of Veterinary Clinics*, 35(5), 237-239.
- Sullivan, M., & Lee, R. (1989). Radiological features of 80 cases of diaphragmatic rupture. *Journal of Small Animal Practice*, 30, 561-566.
- Sullivan, M., & Reid, J. (1990). Management of 60 cases of diaphragmatic rupture. *Journal of Small Animal Practice*, 31, 425-430.
- Yayinggul, R., Bozkan, Z., Bilgen Sen, Z., Kibar Kurt, B., & Belge, A. (2019). Traumatic diaphragmatic hernia in cats: A retrospective study of 15 cases (2016-2017). (2), 205-212.
- Zamirbekova, N., Uzunlu, E.O., & Arıcan, M. (2020). Kedi ve köpeklerde travmatik hernia diyafrenmatika: 40 olgu. *Bozok Veterinary Sciences*, 1(1), 7-12.
- Zhang, Z.Y., He, M.Y., Xie, Y., & Peng, X. (2020). Diagnosis and treatment of a case of chronic diaphragmatic hernia in a dog. *Animal and Poultry Industry*, 31, 125-126.