

# Clinical Staging as Prognostic Indicator for Surgical Decision-Making Tool in Mammary Tumours in Bitches

Urvashi Choudhary<sup>1\*</sup>, Reshma Jain<sup>1</sup>, Brahm Prakash Shukla<sup>1</sup>, Atul Singh Parihar<sup>1</sup>, Pawan Deewan Singh Raghuwanshi<sup>1</sup>, Supriya Shukla<sup>2</sup>

## ABSTRACT

Mammary tumours are the second most common neoplasms in female dogs, following skin tumours and are more prevalent in regions where early spaying is not common. Surgical resection is the gold standard for managing these tumours, providing effective local control, except in cases of inflammatory carcinoma or distant metastases. This study examined the staging and metastases patterns of canine mammary tumours in 25 cases in dogs. Among these 25 animals, 32% were in Stage III, 24% in Stage IV and Stage V, 12% in Stage I and 8% in Stage II. Regional metastases occurred in 10 animals (6 in Stage IV and 4 in Stage V), with thoracic metastases identified in 6 Stage V cases which was confirmed by histopathology of excised tumours. Radiographs showed miliary nodules (<2 mm) in one case and larger pulmonary nodules (>2 mm) in five cases, along with other atypical lesions like pulmonary effusion, cardiomegaly and perihilar nodules. Miliary opacities indicated lymphatic spread, while defined nodules were typical of thoracic metastases. Surgical procedures, including lumpectomy, simple mastectomy and radical mastectomy were chosen based on gross morphology and stage. The dogs with malignant mammary tumours had significantly higher levels of haemoglobin and TLC with neutrophilia, lymphopenia and elevated creatinine compared to those with benign tumours. These findings highlight the need for early detection, accurate staging and personalized surgical intervention to improve prognosis.

**Key words:** Canine mammary tumours, Histopathological classification, Mastectomy, Metastases, TNM staging.

*Ind J Vet Sci and Biotech* (2025): 10.48165/ijvsbt.21.6.09

## INTRODUCTION

There are 5 pairs of mammary glands present in the bitches from pectoral to inguinal region. Mammary tumours are the most common neoplasm in female dogs and occur mostly in countries where dogs are not routinely spayed at an early age. Differentiation between benign and malignant tumours is essential preoperative for determining the patient's prognosis. Malignant mammary tumours have a poor prognosis because of the very high rate of recurrence and distant metastasis. Tumour size, lymph node status and distant metastases under the WHO TNM classification system are helpful in surgical prognosis (Robbins, 2003). A radiographic thoracic and abdominal examination can evaluate the presence of metastases in the lungs and the increase in the volume of lymph nodes (O'Keefe, 1995). Surgical resection is the current gold standard therapy for mammary gland tumours in dogs and considered to be the single most effective method to attain local tumour control with the exception of inflammatory carcinoma or presence of distant metastases (Nimwegen and Kirpensteijn, 2012).

## MATERIALS AND METHODS

This study was undertaken on total 25 clinical cases of mammary tumour in dogs out of total 1857 dogs presented to Veterinary Clinical Complex, College of Veterinary Science & A.H., Mhow, Indore (MP, India) from May to October 2024

<sup>1</sup>Department of Veterinary Surgery and Radiology, College of Veterinary Science and Animal Husbandry, NDVSU, Mhow-453446, Madhya Pradesh, India

<sup>2</sup>Department of Veterinary Pathology, College of Veterinary Science and Animal Husbandry, NDVSU, Mhow-453446, Madhya Pradesh, India

**Corresponding Author:** Dr. Urvashi Choudhary, MVSc Scholar, Department of Veterinary Surgery and Radiology, College of Veterinary Science and Animal Husbandry, NDVSU, Mhow-453446, MP, India. e-mail: curvashi26@gmail.com

**How to cite this article:** Choudhary, U., Jain, R., Shukla, B. P., Parihar, A. S., Raghuwanshi, P. D. S., & Shukla, S. (2025). Clinical Staging as Prognostic Indicator for Surgical Decision-Making Tool in Mammary Tumours in Bitches. *Ind J Vet Sci and Biotech*, 21(6), 50-55.

**Source of support:** Nil

**Conflict of interest:** None

**Submitted** 04/08/2025 **Accepted** 30/09/2025 **Published** 10/11/2025

for staging and metastases patterns. The incidence was calculated as per the formula mentioned in Thrusfield (2005).

The affected dogs were subjected to routine clinico-physiological monitoring on the day of presentation or before surgery. The history pertaining the growth period, involvement of the particular mammary gland, *i.e.* from M1 to M5 (M1 and M2 as cranial and caudo-thoracic pairs, M3 and M4 as abdominal pairs and M5 as inguinal pair), unilateral or bilateral and extent of growth from thoracic to abdominal to

inguinal gland was recorded. Reproductive status in terms of intact or spayed, parity *i.e.*, whether the animal is nullipara, unipara or multipara was also recorded.

The clinical staging of mammary tumour was done by modified WHO TNM system as per Robbins (2003). The TNM system is based on the assessment of the extent of primary tumour (T), the condition of the regional lymph nodes (N) and the absence/presence of distant metastasis (M). Accordingly, the Stage I, II, III, comprised of T1N0M0, T2N0M0 and T3M0M0, while stage IV and V comprised of T any size N1 M0, and T any size N0 or N1 & M1, respectively.

The size of the tumour was identified by using a measuring scale near the tumour. T1, T2 and T3 indicate increasing degrees of extent of the primary tumour from less than 3 cm for T1, 3 to 5 cm for T2 and all those more than 5 cm for T3. N indicates the characteristics of lymph nodes, which was assessed by palpation and scored as N0, without lymph node metastasis; N1, metastasis in lymph node present. If enlargement was present, fine needle aspiration sampling for cytological evaluation of the corresponding lymph node was performed for regional metastases and scored as M0, absence of distant metastases; M1, presence of distant metastases in lungs. Distant metastases in lungs were evaluated radiographically. Well positioned, good quality two view (lateral and ventro-dorsal) of thoracic radiographs were taken for the diagnosis of metastases.

### Surgical Techniques

One of the following six categories of surgical excision of mammary tumours was used as per the merit of the patient as mentioned by Maiti (2022).

**Lumpectomy:** Removal of nodules which were benign, small and non-adherent to the skin or underlying tissues.

**Simple mastectomy:** Removal of gland bearing tumour was done for lesion centrally located within the gland, larger than 1 cm and exhibiting any degree of fixation to skin or fascia.

**En-bloc dissection:** Removal of multiple glands along with their intervening lymph nodes. **Half chain removal:** Removal of gland and adjacent gland 1 of 2 or 4 of 5 in half chain removal. **Unilateral mastectomy:** Removal of entire chain of 5 mammary glands and regional lymph node, if the lymph nodes (axillary/inguinal) were present within the resection zone. **Radical mastectomy:** Removal of bilateral mammary chain, the skin covering them and the four lymph nodes at the same time.

As per the techniques of Sleenckx *et al.* (2011) and Nair (2021), the skin incision was made either by scalpel or by using electrocautery followed by deep dissection, isolation of mass without rupturing the capsule and dissection was done up to the external abdominal muscle fascia. Caudal superficial epigastric artery and veins were identified and ligated using absorbable suture material. The sutures were removed 12-15 days post surgery but in cases of radical mastectomy or unilateral mastectomy where the suture lines were extensive, the sutures were removed only after complete healing had occurred. In all cases healing occurred without any

complications like exudation, edema, inflammation or wound dehiscence. The tumours upon examination were classified according to the diagnostic criteria proposed by Goldschmidt *et al.* (2011) for mammary tumours of dog.

## RESULTS AND DISCUSSION

Total 1857 dogs were presented to Veterinary Clinical Complex, College of Veterinary Science and A.H., Mhow (MP). Out of these, 25 dogs were affected with mammary tumours with prevalence of 1.34%. All 25 canine patients were found to be females only, and 17 had malignant and 8 had benign tumours.

### Clinico-Epidemiology

Mammary tumours were observed in 11 different dog breeds (Table 1). Labrador Retrievers (8 out of 25), German Shepherds (4 out of 25) and Non-Descript dogs (3 out of 25) were the highest prevalent breeds followed by Pomeranians and Golden Retrievers (2 out of 25), and a single case each in Boxers, Shih Tzus, Spitz, Alsations, Saint Bernards and Rottweilers. Among these, the Labrador Retriever was the most commonly affected breed, accounting for 32% of the cases. This might be attributed to the relatively higher population of Labrador and German Shepherd in Mhow region and nearby Indore district. All 25 cases were found in intact bitches. Benign tumours were most prevalent in the 6-11 years age group, while malignant tumours were more common in the 6-13 years age group, indicating that the risk of malignancy increases with age.

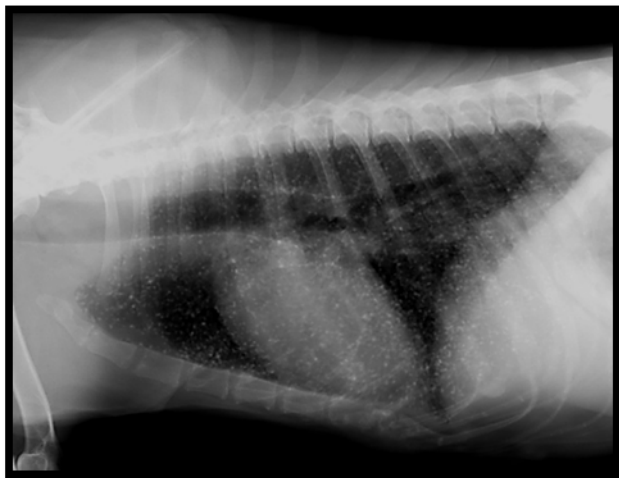
In current study, the highest prevalence of mammary tumours was observed on the right side, affecting 15 dogs, followed by the left side in 5 dogs. Bilateral growth was seen in 3 cases and two dogs had tumours in distant locations on both sides. The majority of mammary tumours had an irregular shape (13 cases). The consistency of these tumours varied, with 9 cases being irregular, hard and adhered to surrounding tissue, out of these 4 were deeply adhered and 4 tumours were irregular, soft and adhered. Round tumours were also common (12 cases), with 7 cases having a round, hard consistency. Of these 7 round tumours, 4 were pedunculated and 3 were adhered. Ulcers were present on the surface of 6 malignant tumours. The weight of the tumour masses ranged from 90 g to 2250 g (Table 1).

Out of 25 cases, the cases which were in Stage I, II and III had primary tumours with no metastases. However, cases in the Stage IV and V had very aggressive tumours with metastases present in axillary/inguinal lymph nodes and thorax. Lymph nodes in all the cases were palpated and were found enlarged in 10 cases. According to current study, 8 (32%) animals were found in Stage III followed by 6 (24%) animals each in Stage IV and Stage V, 3 (12%) animals in Stage I and 2 (8%) animals in Stage II (Table 1). Regional metastases was found in total 10 animals (6 cases in Stage IV and 4 cases in Stage V). This was in contrast to Gangwar

(2022), who found that the majority of the animals showed TNM stage III (76.19%), followed by stage II and stage IV (7.14%) and least showed stage I and stage V (4.76%). Gundim *et al.* (2016) observed maximum cases of Stage I (20) followed by Stage IV (14), Stage II, III (12, 12) and least cases of Stage V (5). The TNM classification was also used by Nair (2021) and Lekshmi (2021) with maximum neoplasms found to be in Stage V. In their study they concluded about the poor prognosis of females with distant metastases as compared to that present in regional lymph nodes alone. Kudnig and Seguin (2012) also described about the significance of TNM staging of tumours for surgical decision making.

### Thoracic Radiography

Thoracic metastases were found in 6 cases of Stage V which were later confirmed by histopathological examination of the excised tumour masses. The radiographic findings of pulmonary metastases were miliary nodules (<2 mm) (Fig. 1) in one case and pulmonary nodules (>2 mm) (Fig. 2) of various sizes and other opacity in 5 cases. Along with pulmonary nodules, there were other atypical metastatic lesions such as opacities due to pulmonary effusion, cardiomegaly and perihilar nodules etc.

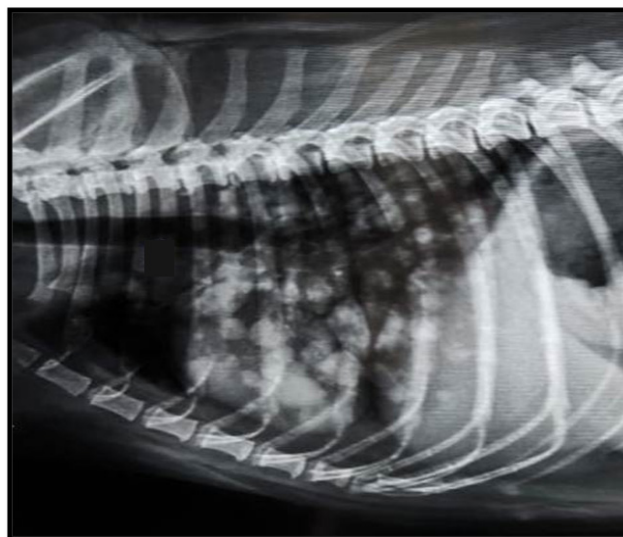


**Fig. 1:** Skiagram showing miliary nodules throughout the lungs in right lateral view

The signs of thoracic metastases are similar to those found in abnormal interstitial lung pattern. Miliary small sized opacities are indicative of lymphatic spread through axillary and inguinal lymph nodes into tracheobroncheal, mediastinal and sternal lymph nodes. Multiple, sharply defined nodular opacities are the most common manifestation of thoracic metastases of malignant mammary neoplasms. The radiographic features of large circular opacities/cannonball configurations are suggestive of metastatic lesion of osteosarcomas and chondrosarcomas (Kealy and McAllister, 2004; Thrall, 2018). Nair (2021) concluded about the signs of early pulmonary metastases based on the size fine dots to single cavity mass including pulmonary micronodules, nodules, solid masses in the ascending order of their sizes,

signs of progressive pulmonary metastases were large solid masses (>30 mm) throughout the lungs. Similar findings were also recorded by Armbrust *et al.* (2012) and Lekshmi (2021).

In majority of the cases left/right lateral radiograph alone was sufficient for identifying the lesions, but the extent of the lesions and extra pulmonary changes were well appreciated in ventro-dorsal thoracic views. Thoracic radiographs were found highly effective in detecting distant metastatic through lymphatic and haematogenic route. This was in agreement with Brinkman *et al.* (2006), Ober and Barber (2006) and Gowthami (2017), who studied the clinical relevance of the ventro-dorsal (VD) versus dorsoventral (DV) thoracic radiograph in dogs to predict staging of neoplasms.



**Fig. 2:** Skiagram showing cannon ball metastases throughout the lung parenchyma in right lateral view

### Surgical Technique

In present study, all 25 dogs with mammary tumours were subjected to surgery and the choice of the surgical technique was made according to merit of the patient as shown in Table 1. Simple mastectomy was performed in total 9 (36%) cases in which there were 5 cases in Stage III followed by 2 cases in Stage II and 1-1 case in Stage I and IV each. Unilateral mastectomy was done in total 4 (16%) cases having 2 cases in Stage V and 2 cases of Stage IV. En-block dissection was performed in 5 (20%) cases, out of that, 2 cases each in Stage IV and Stage V, and 1 case in Stage III. Radical mastectomy was performed in 3 (12%) cases in which 2 cases were in Stage V and 1 case in Stage IV. Lumpectomy and half chain mastectomy was done in 2 (8%) cases each of Stage I and Stage III, respectively.

The surgical technique for removing the tumour was selected on the basis of the size of the tumour, location and consistency, clinical stage, condition of the patient and accordingly, the surgical excision was performed as mentioned by Hedlund (2002), Farese *et al.* (2018) and Maiti (2022). Radical mastectomy and en-block dissection was performed in those cases where metastases had already

**Table 1:** Clinical history, gross morphology, TNM staging and type of surgical technique of mammary tumours followed in intact female dogs (n=25)

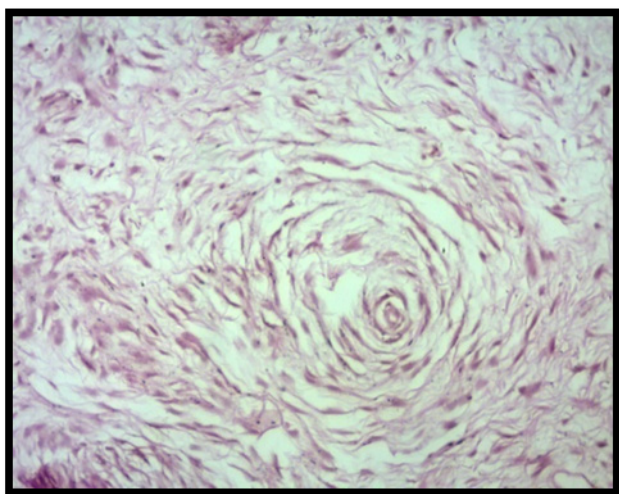
Case No.	Breed	Age (yrs)	Parity	Location	Duration of growth	Consistency	Surface Ulcer	Weight (gm)	TNM Evaluation	Stage	Type of Surgical Technique
C1	Non-descript	6	Multipara	Left M4	2 months	Round, Hard and Pedunculated	No	310	T2N0M0	II	Simple Mastectomy
C2	Labrador	8	Unipara	Right M2 and M3	4 months	Round, Hard and Pedunculated	No	355	T2N0M0	II	Simple Mastectomy
C3	Golden Retriever	6.5	Nullipara	Right M5	7 months	Round, Soft and Pedunculated	No	418	T3N0M0	III	Simple Mastectomy
C4	Labrador	7	Nullipara	Left M4	3 months	Round, Hard and Pedunculated	No	281	T3N0M0	III	Simple Mastectomy
C5	Labrador	8	Nullipara	Right M1	4.5 months	Irregular, Hard and Adhered	No	90	T1N0M0	I	Lumpectomy
C6	Shih Tsu	8.5	Nullipara	Right M5	5 months	Round, Hard and Pedunculated	No	149	T1N0M0	I	Lumpectomy
C7	Pomeranian	10	Nullipara	Left M1	2 years	Round, Hard and Adhered	No	160	T1N0M0	I	Simple Mastectomy
C8	GSD	11	Nullipara	Right M4 and M5	6 months	Irregular, Soft and Adhered	No	301	T3N0M0	III	Half Chain Mastectomy
C9	Boxer	6	Multipara	Right M4 and M5	2.5 months	Irregular, Hard and Adhered	No	527	T3N1M1	V	En-block dissection and Chemotherapy
C10	Labrador	8.5	Unipara	Right M2 and M3	1.5 months	Irregular, Hard and Adhered	No	534	T3N0M0	III	Half Chain Mastectomy
C11	Labrador	11	Multipara	Right M2 & Left M4	4.5 months	Irregular, Soft and Adhered	No	900	T3N1M0	IV	Unil. Mastectomy
C12	Rottweiler	9	Unipara	Right M4 and M5	2 months	Irregular, Hard and Adhered	No	743	T3N0M0	III	En-block dissection
C13	Alsatian	7	Nullipara	Right M5	1.5 months	Irregular, Hard and Adhered	Yes	591	T3N1M0	IV	Simple Mastectomy
C14	Saint Bernard	5	Unipara	Right M1 and M2	3 months	Round, Hard and Adhered	No	623	T3N1M0	IV	En-block dissection
C15	GSD	10	Unipara	Left M5	15 days	Round, Hard and Adhered	No	456	T3N0M0	III	Simple Mastectomy
C16	Spitz	13	Unipara	Right M3, M4 & M5	3 months	Irregular and deeply Adhered	No	450	T3N1M1	V	Unil. Mastectomy
C17	Non-descript	13	Nullipara	Right M3 and M5	1 month	Round, Soft and Adhered	No	718	T3N0M0	III	Simple Mastectomy
C18	Pomeranian	11	Multipara	Right M2 and M4	15 days	Irregular and deeply Adhered	Yes	1020	T3N1M0	IV	Unil. Mastectomy and Chemotherapy
C19	Labrador	9	Multipara	Right M4 & Left M3	1 month	Round, Soft and Adhered	Yes	873	T3N1M0	IV	Radical Mastectomy
C20	GSD	9	Nullipara	Bilateral M2 to M5	1.5 months	Irregular and deeply Adhered	Yes	2250	T3N1M1	V	Radical Mastectomy
C21	Non-descript	7	Multipara	Left M1 to M5	1.5 months	Irregular and deeply Adhered	Yes	912	T3N0M1	V	Unil. Mastectomy
C22	Golden Retriever	10	Nullipara	Bilateral M3 to M5	1 month	Irregular, Soft and Adhered	No	490	T3N0M1	V	En-block Mastectomy
C23	Labrador	8.5	Multipara	Bilateral M4 and M5	1 month	Irregular, Soft and Adhered	No	1060	T3N1M1	V	Radical Mastectomy
C24	Labrador	7	Nullipara	Right M4 and M5	1.5 month	Round, Soft and Adhered	Yes	875	T3N1M0	IV	En-block dissection
C25	GSD	9	Multipara	Right M5	2 months	Round, Soft and Adhered	No	117	T3N0M0	III	Simple Mastectomy

been established in regional lymph nodes. Complete removal of the tumours and regional lymph nodes along with surrounding healthy tissue was performed in those cases. Enlarged lymph nodes were excised in 6 cases of Stage IV and 4 cases of Stage V to limit the lymphatic spread as per Tuohy *et al.* (2009). Simple mastectomy and lumpectomy was done in small sized or pedunculated tumours. Unilateral mastectomy and half chain removal was done according to the location of the tumour. This was in accordance with the procedure suggested by Kudnig and Seguin (2012) and Nair (2021).

The dogs with malignant mammary tumours showed significantly higher levels of haemoglobin ( $10.82 \pm 0.33$  g/dL), TLC ( $26.12 \pm 3.01$  thousand/ $\mu$ L), neutrophils ( $84.94 \pm 2.02\%$ ) and lower lymphocytes ( $11.88 \pm 1.63\%$ ) compared to those with benign tumours ( $15.12 \pm 0.74$  g/dL,  $9.49 \pm 0.42$  thousand/ $\mu$ L,  $76.75 \pm 2.29\%$  and  $21.12 \pm 2.36\%$  respectively). There was no significant difference in the percentage of monocytes, eosinophils, or basophils. Benign tumours showed significantly lesser creatinine levels ( $0.93 \pm 0.06$  mg/dL) as compared to malignant tumours ( $1.42 \pm 0.16$  mg/dL). However, no significant difference was observed in SGOT levels between malignant and benign tumours.

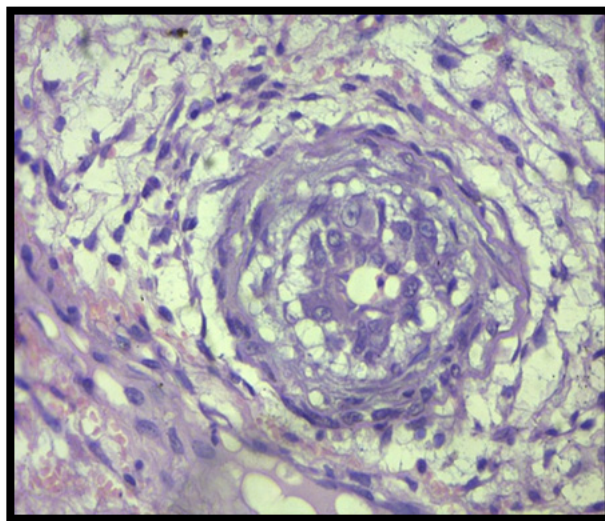
### Histopathological Examination

In present study tumours were classified on the basis of criteria given by Goldschmidt *et al.* (2011). Out of 25 cases, malignant neoplasms were found in 68% (17/25) and benign neoplasms in 32% (8/25) cases. Out of 8 benign neoplasms, prevalence of simple adenoma was 20% (5/25), and fibroadenoma in 12% (3/25) (Fig. 3). Out of 17 malignant neoplasms the prevalence of malignant epithelial neoplasms were 48% (12/25), malignant mesenchymal neoplasms were 16% (4/25) and malignant epithelial neoplasm-special types 4% (1/25). The malignant epithelial neoplasms were classified into carcinoma-tubular (1/25, 4%), carcinoma *in situ* (1/25, 4%), carcinoma micropapillary invasive (4/25, 16%),

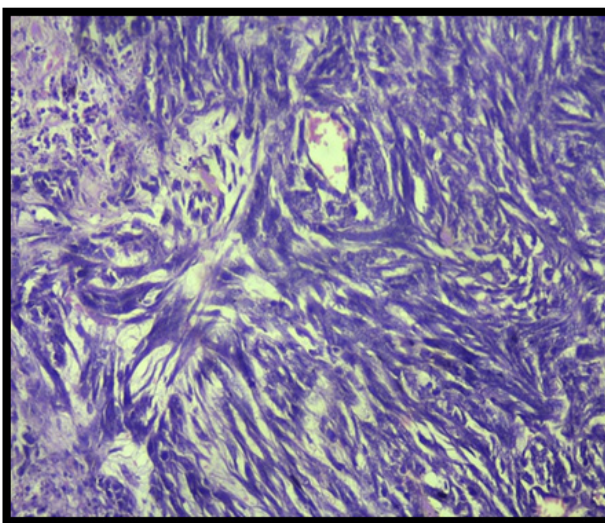


**Fig. 3:** Fibroadenoma: whorling pattern of connective tissue surrounding acini (H&E X400)

carcinoma complex type (2/25, 8%), carcinoma and malignant myoepithelioma (1/25, 4%) (Fig. 4), carcinoma arising in complex/mixed tumour (1/25, 4%) and comedocarcinoma (1/25, 4%). The malignant epithelial neoplasm special types were classified into lipid rich secretory carcinoma found in one case with 4% prevalence. The malignant mesenchymal neoplasm were classified into fibrosarcoma (1/25, 4%) (Fig. 5), haemangiosarcoma (1/25, 4%), osteosarcoma (1/25, 4%) and chondrosarcoma (1/25, 4%).



**Fig. 4:** Malignant myoepithelioma: whorling pattern with low mitotic figures (H&E X400)



**Fig. 5:** Fibrosarcoma: staghorn appearance of fibrous tissue (H&E X200)

### CONCLUSION

This study highlights the prevalence, clinical staging and management of mammary tumours in dogs, offering insights into their diagnosis, surgical treatment and prognosis. TNM staging of tumours formed the basis of streamlining surgico-therapeutic approaches. On the basis of observations, it

was concluded that out of total 1857 dogs, 25 (1.34%) cases were of mammary tumours found especially in elderly intact bitches with 68% of those 25 tumours were malignant and 32% were benign. Most frequent malignant tumours were carcinoma micropapillary invasive and among benign category simple adenomas were most prevalent. Size of tumour (T), enlarged lymph nodes (N), thoracic radiographic findings of metastases (M) played an important role to identify the clinical stage of particular dog. Surgery was the ultimate effective choice to improve the quality of life of patients as most of the owners were reluctant to opt for adjuvant chemotherapeutic protocol.

## ACKNOWLEDGEMENT

Authors would like to express the heartfelt gratitude to the Dean, College of Veterinary Science and A.H., Mhow and the Department of Surgery and Radiology, Mhow for providing necessary facilities during the course of study.

## REFERENCES

- Armbrust L.J., Biller, D.S., Bamford, A., Chun, R., Garrett, L.D., & Sanderson, M.W. (2012). Comparison of three-view thoracic radiography and computed tomography for detection of pulmonary nodules in dogs with neoplasia. *Journal of the American Veterinary Medical Association*, 240, 1088-1094.
- Brinkman, E.L., Biller, D., & Armbrust, L. (2006). The clinical usefulness of the ventrodorsal versus dorsoventral thoracic radiograph in dogs. *Journal of the American Animal Hospital Association*, 42, 440-449.
- Farese, J.P., Bacon, N.J., Liptak, J. M., & Kow, K. (2018). Introduction to oncologic surgery for the general surgeon. In: Tobias, K. M. and Johnston, S. A. (ed.), *Veterinary Surgery: Small Animal*. St. Louis: Elsevier Saunders, pp. 1265-1299.
- Goldschmidt, M., Pena, L., Rasotto, R., & Zappulli, V. (2011). Classification and grading of canine mammary tumors. *Veterinary Pathology*, 48(1), 117-131.
- Gowthami, N.G.V. (2017). Computerized radiographic studies of thorax in geriatric dogs. *M.V.Sc. and A.H. Thesis*. Sri Venkateswara Veterinary University, Thirupati, India, 148p.
- Gundim, L.F., De Araujo, C.P., Blanca, W.T., Guimarães, E.C., & Medeiros, A.A. (2016). Clinical staging in bitches with mammary tumors: Influence of type and histological grade. *Canadian Journal of Veterinary Research*, 80(4), 318-322.
- Hedlund, S.C. (2002). Surgery of female reproductive system, mammary tumor. In: Welchfossom T. Mosby (ed.). *Text Book of Small Animal Surgery*, 2<sup>nd</sup> edn., St. Louis, Missouri, pp. 632-638.
- Kealy, J. K., & McAllister, H. (2004). *Diagnostic Radiology and Ultrasonography of the Dog and Cat*. 4<sup>th</sup> edn., Saunders, Elsevier, St. Louis, pp. 210-213.
- Kudnig, S.T., & Séguin, B. (2012). *Surgical Oncology in Veterinary Practice*. 1<sup>st</sup> edn., John Wiley and Sons, New Jersey, pp. 298-320.
- Lekshmi, S.L. (2021). Radiographic evaluation of thorax to aid staging of superficial and mammary neoplasms in dogs. *M.V.Sc. and A.H. Thesis*. Kerala Veterinary and Animal Sciences University, Thrissur, India.
- Maiti, S.K. (2022). Canine mammary cancer- Updates on diagnostic and therapeutic approaches. *Proceedings of 44<sup>th</sup> Annual Congress of Indian Society for Veterinary Surgery and National Symposium* held at GBPAUT, Pantnagar, 24-26 February, pp. 163.
- Nair, S.S. (2021). Streamlining surgical approaches of skin and mammary tissue / subcutaneous neoplasms in dogs with special reference to neo-adjuvant and adjuvant chemotherapeutic protocols. *Ph.D Thesis*. Kerala Veterinary and Animal Sciences University, Thrissur, India.
- Nimwegen, S., & Kirpensteijn, J. (2012). Specific disorders. In: *Veterinary Surgery Small Animal*. Tobias, K.M and Johnston, S.A. St Louis Elsevier, pp. 1508-1524.
- O'Keefe, D.A. (1995). Tumors of the Genital System and Mammary Glands. In: Ettinger, S.J., Feldman, E.C. (ed). *Veterinary Internal Medicine*. W.B. Saunders Company, Philadelphia, pp 1699-1704.
- Ober, C.P., & Barber, D. (2006). Comparison of two- versus three-view thoracic radiographic studies on conspicuity of structured interstitial patterns in dogs. *Veterinary Radiology and Ultrasound*, 47, 542-545.
- Robbins, M. (2003). Reproductive oncology. *Textbook of Small Animal Surgery*, 3<sup>rd</sup> edn., Slatter D., Saunders Publication, Philadelphia, pp. 2439-2444.
- Sleeckx, N., De Rooster, H., Veldhuis Kroeze, E.J.B., Van Ginneken, C., & Van Brantegem, L. (2011). Canine mammary tumours - An overview. *Reproduction in Domestic Animals*, 46(12), 1112-1131.
- Thrall, D.E. (2018). *Text Book of Veterinary Diagnostic Radiology*. 7<sup>th</sup> edn., Saunders, Elsevier, pp. 567- 733.
- Thrusfield, M. (2005). *Veterinary Clinical Studies. Veterinary Epidemiology*, 3<sup>rd</sup> edn., Blackwell Science Ltd, Oxford, UK, p. 53.
- Tuohy, J.L., Milgram, J., Worley, D.R., & Dernell, W.S. (2009). A review of sentinel lymph node evaluation and the need for its incorporation into veterinary oncology. *Veterinary Comparative Oncology*, 7, 81-91.