

Volvulus of Gravid Uterine Horn in a Pregnant Cat: First Report in India

Jignesh J. Parmar*, Urja B. Patel., Arnold R. Mecvan, Aditya I. Shah, Shital K. Patel, Ankit S. Prajapati, Kamlesh K. Hadiya

Ind J Vet Sci and Biotech (2025): 10.48165/ijvsbt.21.5.36

Torsion is the twisting of an organ around its own axis, while volvulus is the rotation of an organ around its mesenteric axis. Uterine torsion is defined as the twisting of a uterine horn or uterine body about the longitudinal axis (Roberts, 1971). Uterine torsion is an uncommon complication of pregnancy in the cat (Riyard *et al.*, 2000). Uterine torsion is life threatening both for the pregnant cat and fetuses, and its aetiology is unclear (Tohumcu *et al.*, 2021), but loosened uterine ligaments, uterine contractions, fetal movements, maternal physical activity during pregnancy are the possible predispositions for the torsion (Biller and Haibel, 1987). There are published reports on the uterine torsion, but a very few reports of uterine twisting at the base of the uterine horn and ovarian end causing volvulus of uterine horn are available in cats (Thilagar *et al.*, 2005). This paper presents a first report of very rare volvulus of gravid uterine horn in a pregnant cat in India.

CASE HISTORY AND OBSERVATIONS

A three years old 4 kg full term pregnant feral cat was presented with history of straining, lethargy and off feed. On presentation, clinical examinations revealed mildly distended abdomen with palpable fetuses without any movement. Per vaginal examination revealed absence of palpable fetus in birth canal. The physiological parameters revealed rectal temperature 102° F, respiration rate 12/min and heart rates 100 beats/min. The haematological parameters revealed WBC counts $12.07 \times 10^3/\mu\text{L}$, lymphocytes $1.23 \times 10^3/\mu\text{L}$, monocytes $1.09 \times 10^3/\mu\text{L}$, neutrophils $9.69 \times 10^3/\mu\text{L}$, eosinophils $0.05 \times 10^3/\mu\text{L}$, platelets $205 \times 10^3/\mu\text{L}$, but haemoglobin was only 5.3 g/dL. Blood smear examination was negative for haemoprotezoa.

The ultrasonographic examination of gravid uterus revealed no cardiac activity or movement of fetuses (Fig. 1). So, Cesarean was planned immediately to remove fetuses and to extend the life of the cat.

TREATMENT AND DISCUSSION

Pre-operatively, the animal was medicated with subcutaneous Inj. Atropine sulphate 0.04 mg/kg b.wt. General anaesthesia was induced using intravenous Inj. Ketamine HCl @ 5 mg/kg

Veterinary Clinical Complex, College of Veterinary Science and Animal Husbandry, Kamdhenu University, Anand-388001, Gujarat, India

Corresponding Author: Dr. Jignesh J. Parmar, Assistant Professor, Department of Veterinary Clinical Complex, College of Veterinary Science and AH, Kamdhenu University, Anand-388001, Gujarat, India. e-mail: jigneshparmar2000@gmail.com; jjparmar@kamdhenuuni.edu.in

How to cite this article: Parmar, J. J., Patel, U. B., Mecvan, A. R., Shah, A. I., Patel, S. K, Prajapati, A. S., & Hadiya K. K. (2025). Volvulus of Gravid Uterine Horn in a Pregnant Cat: First Report in India. *Ind J Vet Sci and Biotech*, 21(5), 181-183.

Source of support: Nil

Conflict of interest: None

Submitted 11/07/2025 **Accepted** 12/08/2025 **Published** 10/09/2025

and Inj. Diazepam @ 0.5 mg/kg body weight along with Inj. RL 30 mL as a total dose, Inj. Ceftriaxone and Tazobactam @ 15 mg/kg and Inj. Meloxicam @ 0.1 mg/kg. The ventral midline laparotomy revealed dark red colour uterine horn with serosal disruption and more than three folds of 360° rotation between ovarian end and cervical end of left uterine horn (Fig. 2, 3). So, the case was diagnosed as a volvulus of left uterine horn and ovariohysterectomy was performed (Fig. 4, 5).

The abdominal cavity was washed with 0.9% normal saline and laparotomy wound was closed with Polyglactin 910 no. 3.0 by interrupted suture pattern. The skin was sutured by non-absorbable suture no. 3.0 by interrupted suture pattern. Post-operatively the cat was given Inj. Ceftriaxone and Tazobactam @ 15 mg/kg and Inj. Meloxicam @ 0.1 mg/kg intravenously for five days along with daily antiseptic dressing till healing and haematinic oral liquid. The skin stitches were removed on day 12 post-operatively and the cat recovered without any complications. Two dead fetuses were recovered from left horn of the gravid uterus (Fig. 6), while the right horn was small empty.

Uterine torsion is uncommon in cats and very few cases have been reported. It may be associated with the final third stage of gestation or just before parturition (Thilagar *et al.*, 2005). But the volvulus is very rarely reported in cats. To the authors' knowledge, this is perhaps the first report of volvulus of gravid uterine horn in cat in India. In the present

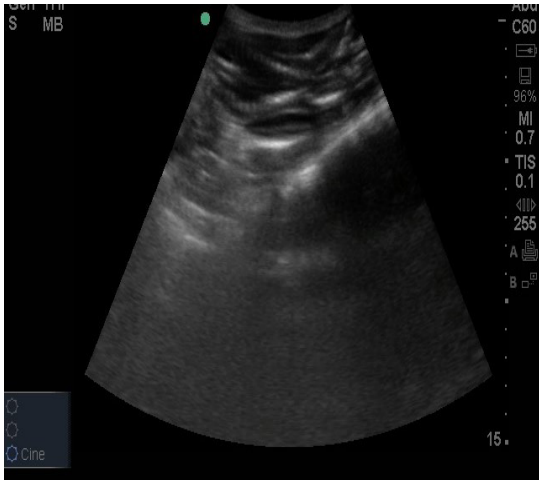


Fig. 1: USG image of dead fetus

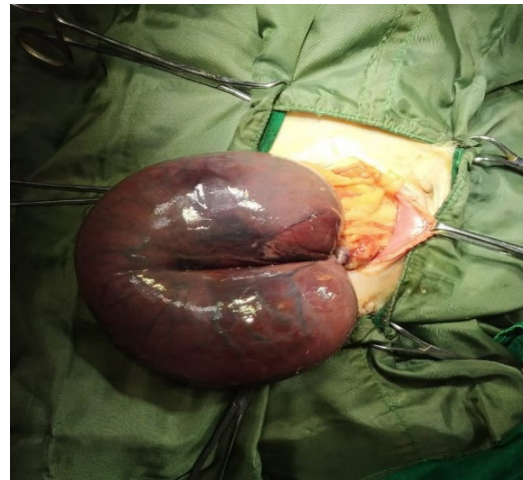

Fig. 2: Uterine volvulus with serosal tear

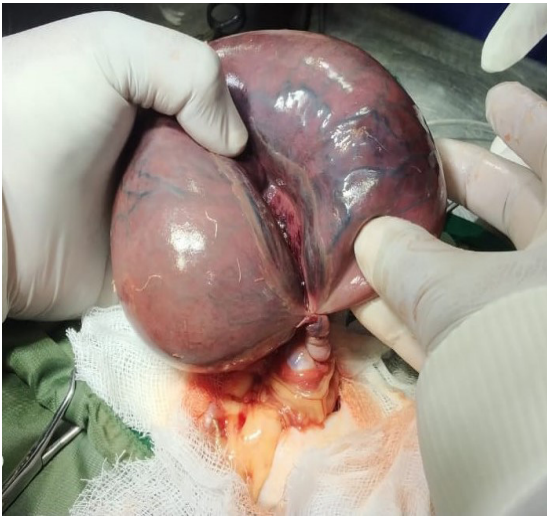


Fig. 3: More than three folds of 360° rotation between ovarian and cervical end of gravid horn

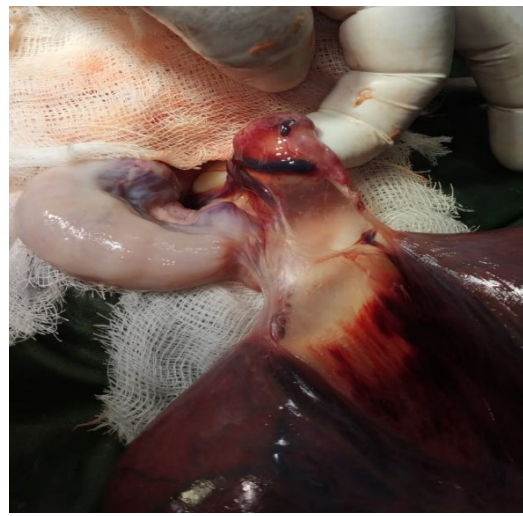


Fig. 4: Gravid horn after defolding and non-gravid horn

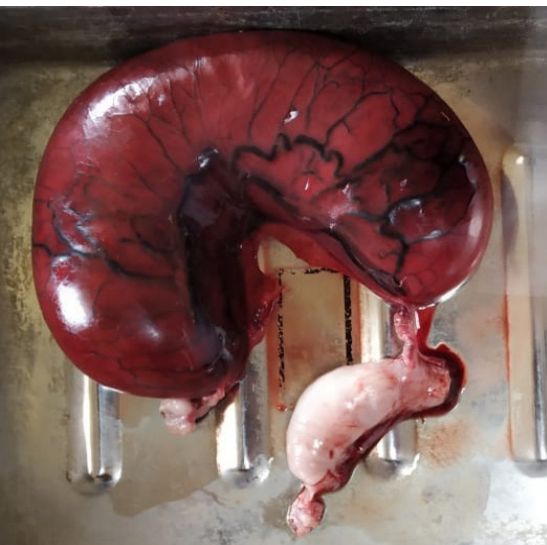


Fig. 5: Gravid and non-gravid uterine horns

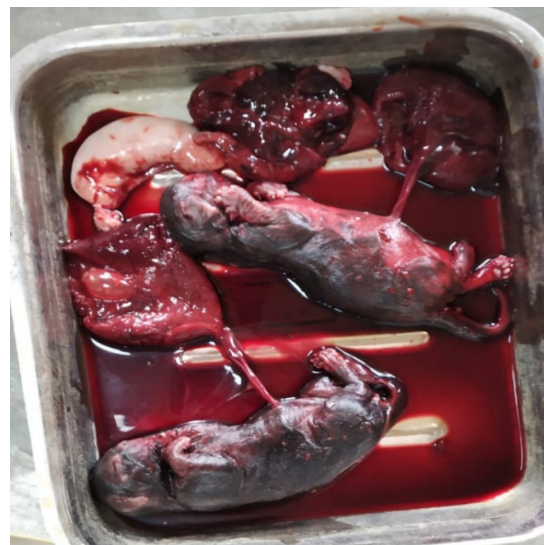

Fig. 6: Two dead fetuses

case history of full term pregnancy with straining, lethargy, off feed, and clinical and USG finding tempted us to suspect it a case of dystocia with dead fetuses, but further laparotomy confirmed the case of uterine volvulus.

Clinically mildly distended abdomen with palpable non-moving fetuses, and their absence in birth canal are not specific of dystocia or uterine volvulus, and laparotomy only can give confirmative diagnosis (Tohumcu *et al.*, 2021). On laparotomy dark red colour uterus with serosal disruption was observed due to compromised blood circulation and necrosis of uterine tissues. In the present case the physiological parameters were within normal limits with low haemoglobin concentration. Hendy and Elgohary (2023) reported normal rectal temperature, tachycardia and tachypnea and pale mucous membrane in cat with uterine torsion. Kuroda *et al.* (2017) also reported rapid respiration and anaemia in cat with uterine torsion. Ridyard *et al.* (2010) reported severe, mildly regenerative anaemia and neutrophilia in cat with uterine torsion which was improved on subsequent days post-operatively. The abdominal ultrasound is essential for the diagnosis of fetal death and the presence of free fluid (Dal-Bo *et al.*, 2013). In this case ultrasonographic examination of gravid uterus revealed no cardiac activity and movement of fetus, but it did not confirm uterine volvulus. The uterine volvulus was confirmed at the time of laparotomy only. Cesarean section is choice of treatment if fetus is viable. The endotoxins and inflammatory mediators release from necrosed tissue lead to severe metabolic alterations in cats (Ridyard *et al.*, 2010). Thus, prognosis and outcome of such cases are favorable after ovariohysterectomy improving survival rate. In the present case successful recovery was achieved through timely diagnosis, and surgical treatment with supportive medications.

In summary, the uterine volvulus is rare in cats. A three years old cat with volvulus of gravid uterine horn was diagnosed through laparotomy and was managed surgically with successful ovariohysterectomy perhaps for the first time in India.

ACKNOWLEDGEMENTS

Authors are grateful to the Principal of the College and University authorities of the Kamdhenu University, Anand for the facilities provided for this work.

REFERENCES

- Biller, D.S., & Haibel, G.K. (1987). Torsion of the uterus in a cat. *Journal of American Veterinary Medical Association*, 191, 1128-1129.
- Dal-Bo, I.S., Correa, T.O., & Ferreira, M.P. (2013). Uterine torsion in domestic feline – Case report. *Ars Veterinaria Jaboticabal*, 29, 88-92.
- Hendy, E., & Elgohary, B. (2023). Unilateral uterine torsion in a pregnant cat. *Journal of Advanced Veterinary Research*, 13(1), 138-140.
- Kuroda, K., Osaki, T., Harada, K., Yamashita, M., Murahata, Y., Azuma, K., Tsuka, T., Ito, N., Imagawa, T., & Okamoto, Y. (2017). Uterine torsion in a full-term pregnant cat. *Journal of Feline Medicine and Surgery Open Reports*, 3(2), 1-4.
- Ridyard, A.D., Welsh, E.A., & Gunn-Moore, D.A. (2000). Successful treatment of uterine torsion in a cat with severe metabolic and haemostatic complications. *Journal of Feline Medicine and Surgery*, 2, 115-119.
- Roberts, S.J. (1971). *Veterinary Obstetrics and Genital Diseases (Theriogenology)*. Ithaca, New York, USA pp 186-285.
- Thilagar, S., Yew, Y.C., Dhaliwal, G.K., Toh, I., & Tong, L.L. (2005). Uterine horn torsion in a pregnant cat. *Veterinary Record*, 157(18), 558-560.
- Tohumcu, V., Ciplak, A.Y., & Aydin, S. (2021). A unilateral horn torsion in a pregnant Angora cat. *Ataturk University Journal of Veterinary Sciences*, 1(1), 14-17.