

Clinico-Pathology and Surgical Management of Leiomyosarcoma in Dog: A Case Report

Priya Khandelwal*, Kuldeep Singh Gurjar, Rakesh Mishra, Annu Rathore, Naveen Kumar

Ind J Vet Sci and Biotech (2025); 10.48165/ijvsbt.21.6.35

A malignant smooth muscle tumour of mesenchymal origin, leiomyosarcoma can develop anywhere in the body. Smooth muscle is the site of this slow-growing, locally invasive, malignant tumour, which usually spreads slowly. Deep dermal smooth muscle, arrector pili, or vascular areas in the genital region can all give birth to dermal smooth muscle tumours (Enzinger *et al.*, 2001). They are identified as angioleiomyomas and angio-leiomyosarcomas, pilo-leiomyomas and pilo-leiomyosarcomas, or genital leiomyomas and leiomyosarcomas, respectively (Liu and Mikaelian, 2003). Dermal smooth muscle tumours occur most frequently in dogs, cats and ferrets (Bahl *et al.*, 2020). Surgical resection is the treatment most used for leiomyosarcoma. In humans and most other animals, leiomyosarcomas are relatively common in the visceral organs, especially the gastrointestinal tract and female genital tract, and in the spleen in dogs (Enzinger *et al.*, 2001; Cooper and Valentine, 2002). Leiomyosarcoma rarely occurs in other organs; only a few cases in the oral cavity, oesophagus, and urinary bladder have been reported in humans and animals (Enzinger *et al.*, 2001; Cooper and Valentine, 2002). Subcutaneous leiomyosarcoma is extremely rare in animals. This document puts on record a clinico-pathological study and surgical management of leiomyosarcoma in a dog.

CASE HISTORY AND OBSERVATIONS

An eight years old Golden Retriever female dog was presented to Veterinary Clinical Complex, Apollo College of Veterinary Medicine, Jaipur (India) with history of cutaneous mass. The owner of the dog reported a big lump on thigh region (Fig. 1) and small lump on neck area (Fig. 2) that had grown considerably with time. At clinical examination tumour was sessile and palpable. The condition was suspected as cutaneous leiomyosarcoma.

On systemic investigations complete blood count like haemoglobin, PCV, DLC, MCV, MCH, MCHC was in normal range. In liver function test alkaline phosphatase was found high and albumin was slightly low. In kidney function test blood urea, BUN and phosphorus were slightly low (Table 1). Owner upon advice for surgical resection, agreed and hence surgery was performed.

Department of Veterinary Clinical Complex, Apollo College of Veterinary Medicine, Jaipur-302031, Affiliated to RAJUVAS, Bikaner, India

Corresponding Author: Dr. Priya Khandelwal, Assistant Professor, Veterinary Clinical Complex, Apollo College of Veterinary Medicine, Jaipur-302031, Rajasthan, India. e-mail: priyakhandelwal601@gmail.com

How to cite this article: Khandelwal, P., Gurjar, K. S., Mishra, R., Rathore, A., & Kumar, N. (2025). Clinico-Pathology and Surgical Management of Leiomyosarcoma in Dog: A Case Report. *Ind J Vet Sci and Biotech*, 21(6), 179-181.

Source of support: Nil

Conflict of interest: None

Submitted 02/07/2025 **Accepted** 20/08/2025 **Published** 10/11/2025

Table 1: Haemato-biochemical parameters of dog presented with Leiomyosarcoma

Parameters	Finding	Reference value
Complete Blood Count		
Haemoglobin (g/dL)	14.80	12-18
RBC ($\times 10^6/\mu\text{L}$)	6.93	5.5-8.5
PCV (%)	45	37-55
TLC ($\times 10^3/\mu\text{L}$)	8.80	6-17
Neutrophils (%)	69	60-70
Lymphocytes (%)	26	12-30
Eosinophils (%)	2	2-10
Monocytes (%)	3	3-10
Basophils (%)	0	0-5
Liver Function Test		
Bilirubin Total (mg/dL)	0.19	0-0.4
SGOT/AST (U/L)	25.10	9-49
SGPT/ALT (U/L)	29.90	10-80
ALP (U/L)	308.80	10-100
Total protein (g/dL)	5.92	5.5-7.5
Albumin (g/dL)	2.39	2.6-4.0
Kidney Function Test		
Blood urea (mg/dL)	16.60	18.8-55.4
BUN (mg/dL)	7.76	8.8-25.9
Creatinine (mg/dL)	0.63	0.5-1.6
Uric acid (mg/dL)	0.20	0-2
Calcium (mg/dL)	11.40	8.7-11.8
Phosphorus (mg/dL)	2.63	3-6.2

TREATMENT AND DISCUSSION

The animal was fasted for 12 h before surgery. Site was prepared aseptically. Animal was pre-anesthetized with butorphanol @ 0.4 mg/kg body weight, Diazepam and Ketamine @ 0.01 mg/kg body weight, and atropine. Anaesthesia was induced and maintained with Propofol @ 4 mg/kg body weight. Animal was positioned in lateral recumbency with affected side above. Tissue was surgically removed and skin was repaired in routine manner using polyamide 2.0 monofilament sutures. Post-operative administration of antibiotics, analgesics and dressing of surgical sites were carried out as per the standard protocols. The animal made an uneventful recovery.

The removed tissue masses were fixed in 10% buffered formalin for histopathological examination after processing

by acetone and benzene technique (Culling, 1974). The tissue sections of 4-6 μm thickness were cut and further processed for haematoxylin and eosin (HE) staining as per standard protocol and then tissue sections were permanently mounted with a cover slip using DPX (Bancroft *et al.* 2013).

In gross appearance, the masses were solid with haemorrhages. The cut surfaces of the masses from thigh and neck region were white with partly red areas (Fig. 3). The same findings were noted by Nakamura *et al.* (2010) and Bahl *et al.* (2020). On histopathology the tumour was showing interlacing fascicles of muscle fibers with diminished cytoplasm and pleomorphic nuclei (Fig. 4). The mass was composed of densely packed sheets of interwoven bundles of spindle cells with palisading nuclei separated by a thin collagenous stroma, which corroborated with the observations of Yi *et al.* (2008) and Meuten (2017).

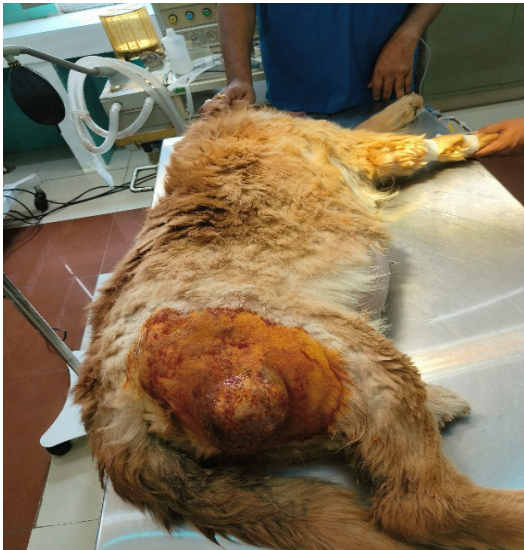

Fig. 1: Showing a big lump on thigh region

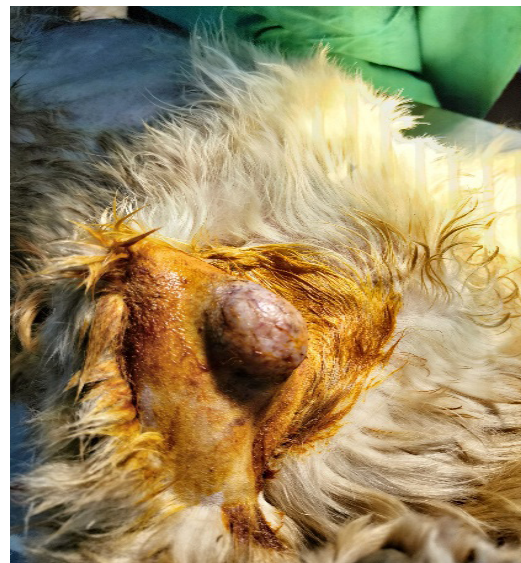

Fig.2: Showing small lump on neck area

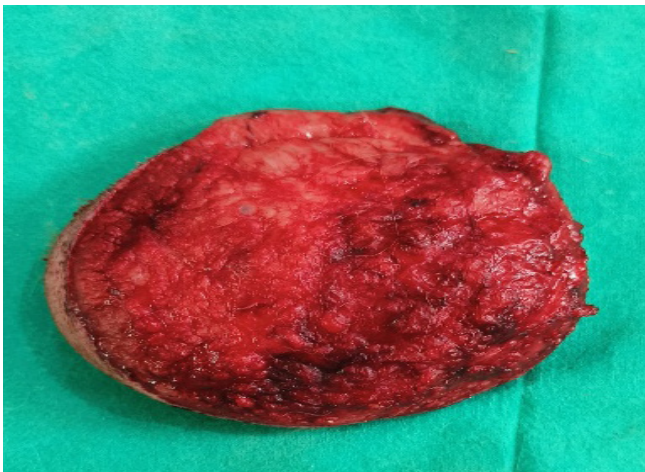


Fig. 3: The cut surface of the tumour removed from thigh region showing white with partly red areas.

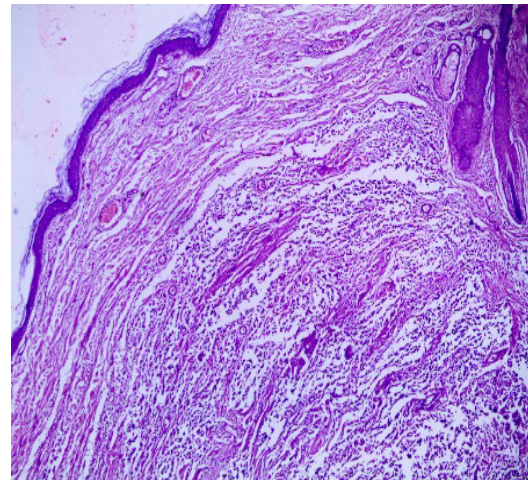


Fig. 4: Microscopic examination showing interlacing fascicles of muscle fibers with diminished cytoplasm and pleomorphic nuclei (H and E stain, 40X)

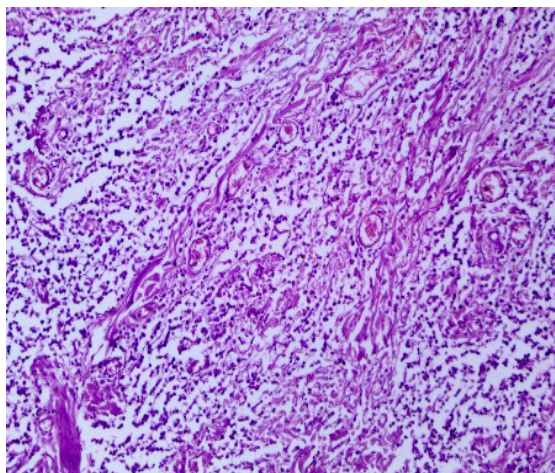


Fig. 5: Microscopic observation showing densely packed sheets of interwoven bundles of spindle cells with palisading nuclei separated by a thin collagenous stroma (H and E stain, 100X)

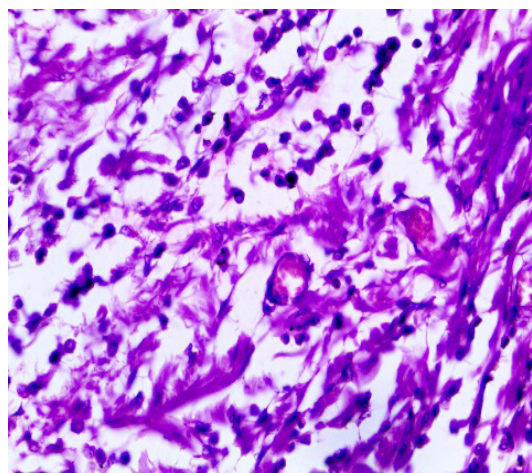


Fig. 6: Microscopic observation showing bundles and fibres in criss-cross pattern having pleiomorphic hyperchromatic nuclei (H and E stain, 400X)

The interlacing fascicles of muscle fibres with diminished cytoplasm and pleomorphic nuclei along with angiogenesis (Fig. 5) noted were in accordance with Jacobsen and Valentine (2000), Jung *et al.* (2009) and Bahl *et al.* (2020). Tumour cells also showed bundles and fibres in criss-cross pattern having pleiomorphic hyperchromatic nuclei (Fig. 6) as reported by Dadhich (2004) and Aihara *et al.* (2019).

Clinical diagnosis of cutaneous leiomyosarcoma is difficult, it can be determined only after histopathological examination. According to Massi *et al.* (2010), cutaneous leiomyosarcoma is an uncommon malignant mesenchymal tumour of smooth muscle origin with an unclear pathogenesis. Numerous animal species, including horses, cows, and cats, have also been shown to have cutaneous tumours of smooth muscle origin (Finnie *et al.*, 1995; Bailey *et al.*, 2003). The present histopathologic characteristics, such as their cigar-shaped nucleus and high concentrations of acidophilic cytoplasm, were quite similar to those of earlier research (Liu and Mikaelian, 2003).

Based on histopathological observations the current tumours were diagnosed as cutaneous leiomyosarcoma. The surgical removal of tumours in time helped recover the patient uneventfully.

ACKNOWLEDGEMENT

The authors are highly thankful to Dean, Dr. C.S. Sharma, Apollo College of Veterinary Medicine, Jaipur for providing necessary facilities, and Prof (Dr.) Rohitash Dadhich, Professor and Head, Department of Veterinary Pathology, PGIVER, Jaipur for assisting histopathological works of this study

REFERENCES

Aihara, N., Sugiyama, J., Baba, H., & Kamiie, J. (2019). Multiple cutaneous pleomorphic leiomyosarcoma in a dog. *Journal of Veterinary Medical Science*, 81(11), 1564-1566.

- Bahl, S., Jangir, B.L., & Narang, G. (2020). Histopathological and immunohistochemical evaluation of leiomyosarcoma in dog. *Haryana Veterinarian*, 59(SI), 109-111.
- Bailey, K.L., Kinsel, M.J., & Connell, K.A. (2003). Multiple cutaneous leiomyomas in the perineum of a horse. *Journal of Veterinary Diagnostic Investigations*, 15, 454-456.
- Bancroft, J.D., Suvarna, S.K., & Layton, C. (2013). *Bancroft's Theory and Practice of Histological Techniques*. 7th edn. British: Churchill Livingstone Elsevier Ltd.
- Cooper, B.J., & Valentine, B.A. (2002). Tumours of muscle. In: *Tumours in Domestic Animals*, 4th edn. (Meuten, D. J. eds.), Blackwell, Iowa, pp. 319-341.
- Culling, C.F.A. (1974). *Histopathological and Histochemical Techniques*. 3rd edn., Butterworths, London.
- Dadhich, R. (2004). Pathological and haemato-biochemical studies of neoplasms in dogs (*Canis familiaris*). *Doctoral Thesis*. Rajasthan Agricultural University, Bikaner, Rajasthan, India.
- Enzinger, F.M., Weiss S.W., & Goldblum J.R. (2001). *Soft Tissue Tumours*, 4th edn., Mosby Year Book, St Louis, MO, pp. 741-744.
- Finnie, J.W., Leong, A.S., & Milios, J. (1995). Multiple pileoleiomyomas in a cat. *Journal of Comparative Pathology*, 113, 201-204.
- Jacobsen, M.C., & Valentine, B.A. (2000). Dermal intravascular leiomyosarcoma in a cat. *Veterinary Pathology*, 37(1), 100-103.
- Jung, J.Y., Kang, S.C., Park, D.S., Lee, E.S., Bae, J.H., & Kim, J.H. (2009). Cutaneous smooth muscle tumours in 3 dogs. *Korean Journal of Veterinary Research*, 49(1), 63-66.
- Liu S.M., & Mikaelian, I. (2003). Cutaneous smooth muscle tumours in the dog and cat. *Veterinary Pathology*, 40, 685-692.
- Massi, D., Franchi, A., Alos, L., Cook, M., Di Palma, S., Enguita, A.B., & Tos, A.P.D. (2010). Primary cutaneous leiomyosarcoma: Clinicopathological analysis of 36 cases. *Histopathology*, 56(2), 251-262.
- Meuten, D.J. (2017). *Tumours in Domestic Animals*. 5th edn., John Wiley & Sons Inc., Germany.
- Nakamura, S.I., Iseda, S., & Une, Y. (2010). Subcutaneous leiomyosarcoma in a common squirrel monkey (*Saimiri sciureus*). *Journal of Veterinary Medical Science*, 72(5), 639-642.
- Yi, J.Y., Kim, Y.H., & Yoon, B.I. (2008). Primary subcutaneous leiomyosarcoma of the hamster hind leg. *Journal of Veterinary Medical Science*, 70(5), 517-520.