

Surgical Management of Incarcerated Bubonoenterocele in a Spitz Dog - A Success Report

N. Sumiran^{1*}, L. Siva Sudarshan², K. Anjali², G. David Jeevanraj¹

Ind J Vet Sci and Biotech (2025): 10.48165/ijvsbt.21.2.28

An inguinal hernia, also called as bubonocele is a protrusion of an organ or part of an organ, fat or tissue through the inguinal ring, *i.e.* the region in the groin where the abdominal musculature meets the hind legs (Byers *et al.*, 2007). Inguinal hernia may be classified as direct or indirect inguinal hernia, congenital or acquired inguinal hernia, unilateral or bilateral inguinal hernia and traumatic or non-traumatic inguinal hernia. Contents of the inguinal hernia include omentum, fat, ovary, uterus, small intestine, colon, bladder or spleen (Kumar *et al.*, 2020). Clinical signs often reflect the size of the hernia and the hernial contents and range from painless inguinal mass to signs related to incarcerated or nonviable small intestine (Waters *et al.*, 1993). The present report describes the successful surgical management of unilateral incarcerated inguinal enterocele in a dog.

CASE HISTORY AND CLINICAL OBSERVATIONS

A ten year old female Spitz dog weighing 6.4 kg was presented to the Veterinary Clinical Complex, College of Veterinary Science, Proddatur (AP, India) with the history of constipation for four days, oliguria, anorexia and swelling for one year in the left inguinal region (Fig. 1). Physical examination revealed a hard oblong mass inside the non-painful, non-reducible swelling. Clinical examination revealed normal heart rate, respiratory rate and rectal temperature. Radiographic examination revealed loss of caudal abdominal stripe and intestinal loops with faecoliths inside the swelling which confirmed it as inguinal hernia (Fig. 2). As the haemato-biochemical parameters such as Hb 13.6 g/dL, PCV 48%, SGPT 141.44 IU/L, Creatinine 1.0 mg/dL were within normal range, it was decided to perform surgery.

TREATMENT AND DISCUSSION

Pre-operative diet restrictions, stabilization of the animal, antibiotic and analgesic therapy, preparation of site and induction of anaesthesia, which are very important, were followed as per the standard protocol. Under general anaesthesia, the first incision was made on the skin lateral to the swelling to expose the intestines, and enterotomy was performed to remove hard faecoliths (Fig. 3) and the enterotomy wound was closed by Lembert and Cushing suture patterns with Polyglycolic acid 2-0 suture material. As

¹Department of Veterinary Surgery and Radiology, College of Veterinary Science, Proddatur, Sri Venkateswara Veterinary University, Tirupati-516360, Andhra Pradesh, India

²Department of Veterinary Clinical Complex, College of Veterinary Science, Proddatur, Sri Venkateswara Veterinary University, Tirupati-516360, Andhra Pradesh, India

***Corresponding author:** Dr. N. Sumiran, Assistant Professor, Dept. of Veterinary Surgery and Radiology, College of Veterinary Science, Proddatur, Sri Venkateswara Veterinary University, Tirupati-516360, India. Email: drnsumiran@gmail.com

How to cite this article: Sumiran, N., Sudarshan, L. S., Anjali, K., & Jeevanraj, G. D. (2025). Surgical Management of Incarcerated Bubonoenterocele in a Spitz Dog - A Success Report. *Ind J Vet Sci and Biotech*, 21(2), 128-130.

Source of support: Nil

Conflict of Interest: None.

Submitted 04/11/2024 **Accepted** 23/12/2024 **Published** 10/03/2025

there were lot of adhesions and unable to differentiate the intestinal loops, rather than extending the incision on weak abdominal musculature, additional ventral midline incision was done and intestinal loops were reduced back by holding the normal intestines. Herniorrhaphy with horizontal mattress sutures performed was found effective (Waters *et al.*, 1993) (Fig. 4). Fenestrated tube was fixed to avoid the collection of fluids. Skin incision and laparotomy wound was closed using standard suturing techniques (Fig. 5).

Post-operatively the animal was given Inj. Ceftriaxone @ 20 mg/kg for five days, Inj. Meloxicam @ 0.3 mg/kg for three days and Tab. Deep TBR as well as Tab. Lyser 5 mg BID per orally for 10 days. Small amounts of water and feed was given 8 h and 12 h post-surgery, respectively, to preserve or increase gastrointestinal blood flow, to prevent ulceration, to stimulate immune system and wound repair (Fossum, 2007). To maintain hydration and to meet the daily maintenance requirements, the animal was given Inj. Normal saline @ 50 mL/kg body weight and Inj. Ringer lactate @ 50 mL/kg body weight intravenously for three days and normal diet introduced gradually.

Seroma formation with loss of fenestrated tube was noticed on 7th post-operative day due to excessive movement and owner's negligence that resulted in dehiscence of inguinal skin sutures. Under general anaesthesia, seroma

was drained, wound sutured and applied bandage. Ten days after second surgery, sutures were removed and the animal recovered uneventfully (Fig. 6).

The important cause of inguinal hernia is enlargement of the entrance to the vaginal process that keeps the inguinal canal open. Shorter inguinal canal with large diameter, anatomical weakness due to altered nutritional or metabolic status, increased intra-abdominal pressure and high estrogen production are the predisposing factors of inguinal hernia in females (Smeak, 2003). Atrophy of the abdominal wall due to old age might be the reason for inguinal hernia in this case. The presence of stomach, a highly distensible organ on left side might be the reason for common incidence of left sided inguinal hernia. Small intestine viability is an important factor in determining whether herniorrhaphy is an elective or an

emergency procedure (Raayat Jahromi *et al.*, 2009). Usually the approach is first through ventral midline for exploration and then the extrabdominal incision subsequently for hernia repair (Smeak, 2003). In the present case obstipation made it as an emergency procedure.

To conclude, unilateral acquired non-traumatic incarcerated inguinal hernia is commonly seen in middle to old age intact bitches. Even though inguinal hernia cases are presented chronically, prognosis is good unless the soft tissues are devitalized. Post-operative complications like seroma formation and wound dehiscence that are commonly seen owing to their location should be minimized with utmost post-operative care and observation. Since inguinal hernia is having hereditary predisposition, affected dogs should not be used for breeding.

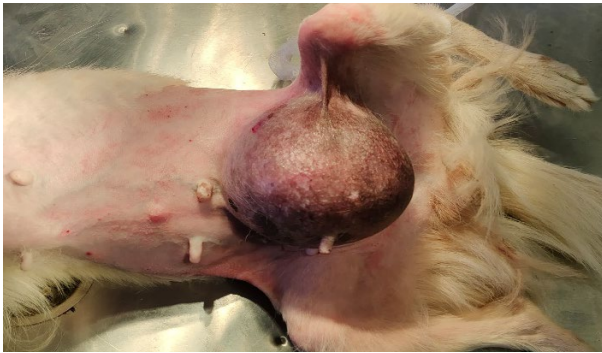

Fig. 1: Pre-operative inguinal swelling

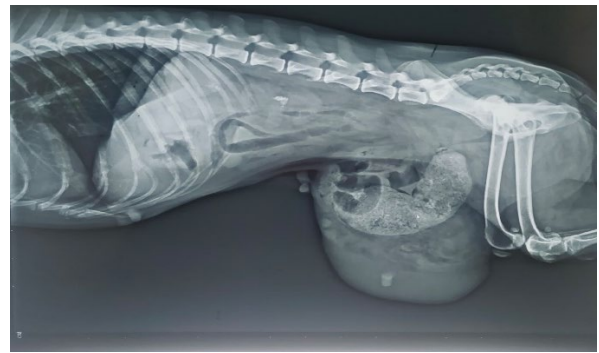


Fig. 2: Skiagram showing loss of caudal abdominal stripe with faecoliths in the herniated intestines

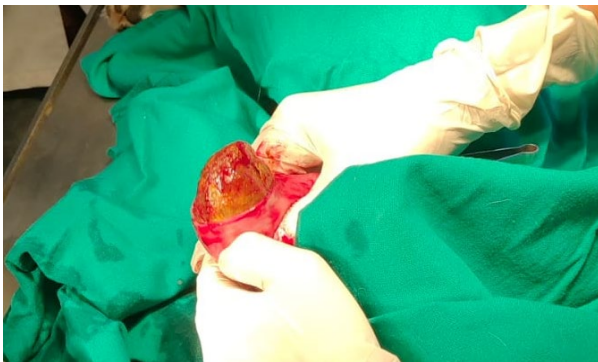


Fig. 3: Removal of faecolith through enterotomy wound

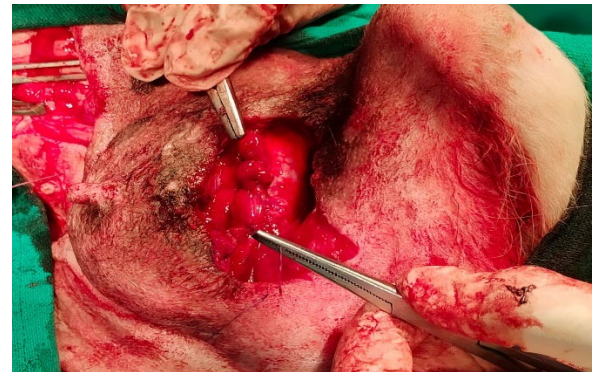


Fig. 4: Herniorrhaphy with horizontal mattress sutures

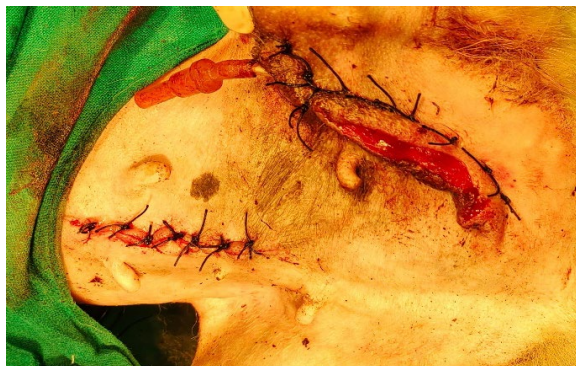

Fig. 5: Immediate post-operative sutured wounds

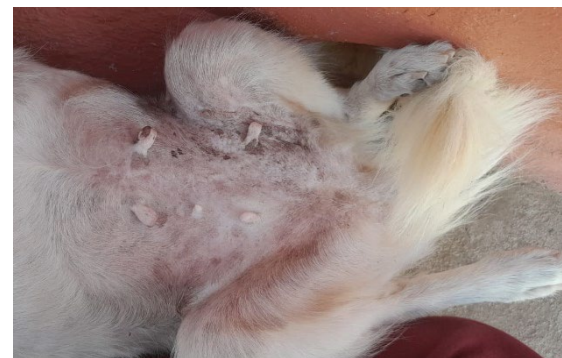

Fig. 6: Complete healing of sutured wound

ACKNOWLEDGEMENT

The authors are grateful to all the staff of Department of Veterinary Surgery and Radiology and Department of Clinical Complex, College of Veterinary Science, Proddatur, Sri Venkateswara Veterinary University for their kind co-operation and support.

REFERENCES

- Byers, C.G., Williams, J.E., & Saylor, D.K. (2007). Pyometra with inguinal herniation of the left uterine horn and omentum in a Beagle dog. *Journal of Veterinary Emergency and Critical Care*, 17(1), 86-92.
- Fossum, T.W. (2007). Surgery of the abdominal cavity. In: *Small Animal Surgery*. 3rd edn. Mosby Elsevier, Philadelphia, USA, pp. 317-338.
- Kumar, V., Kumawat, N.K., Singh, Y.P., Parashar, M.C., Singh, S., Kumari, M., & Kumari, U. (2020). Surgical management of inguinal hernia in Pomeranian bitch: A case report. *Journal of Entomology and Zoology Studies*, 8(5), 2397-2399.
- Raayat Jahromi, A., Dehghani Nazhvani, S., Javdani Gandmani, M., & Mehrshad, S. (2009). Concurrent bilateral inguinal and umbilical hernias in a bitch - A case report. *Veterinarski Arhiv*, 79(5), 517-522.
- Smeak, D.D. (2003). Abdominal Hernias. In: *Text Book of Small Animal Surgery*. 3rd edn. W.B. Saunders, Philadelphia, USA, pp. 452-455.
- Waters, D.J., Roy, R.G., & Stone, E.A. (1993). A retrospective study of inguinal hernia in 35 dogs. *Veterinary surgery*, 22(1), 44-49.

