

Inguinal Hysterocele Mimics Mammary Tumour in Small Breed Dogs

Nikita Gupta*, Vandana Sangwan, Ashwani Kumar, Arun Anand, Shashi Kant Mahajan

ABSTRACT

The study aims to highlight inguinal hysterocele as a common finding in small breed dogs presented with inguinal swelling mimicking mammary tumor. Nine intact female dogs with a history of non-traumatic, left sided inguinal swelling were included in the study. The dogs belonged to the breeds; Dachshund (n=3), Pug (n=2), Pomeranian (n=2) and Non-descript (n=2). Majority of these belonged to middle age group and none had any recent history of parturition relating to swelling. On physical examination, the swelling was hard and firm to touch and non-reducible. The chest radiograph corresponding to inguinal mammary tumor was negative for metastasis in all the dogs. On ultrasonography of inguinal swellings, 3 out of 9 cases (33.33%) were confirmed for inguinal hernia as the small intestines (n=2) or urinary bladder (n=1) were visualized in the swelling. The rest could not be confirmed as the herniated uterine horn and/or omentum did not show any motility. All the dogs were operated under inhalant general anesthesia and a confirmed inguinal hysterocele with either uterine horn or part of it as hernial content with or without other abdominal organs was discovered. Ovariohysterectomy was done in all the cases along with the hernia repair from the same incision site leading to a successful outcome. In conclusion, inguinal swelling in small breed female dogs must be evaluated for hysterocele before proceeding for surgery as it often mimics mammary tumour.

Keywords: Dogs, Hysterocele, Inguinal hernia, Mammary tumour, Ultrasonography.

Ind J Vet Sci and Biotech (2025): 10.48165/ijvsbt.21.1.21

INTRODUCTION

Inguinal canal is a space between internal and external inguinal rings. It is slit like and wider in females as compared to males and serves as a passage for vaginal process in female dogs and spermatic cord in male dogs (Bojrab *et al.*, 2014). Inguinal hernia is less common as compared to umbilical hernia and is rarely traumatic. It can occur in both male and female dogs. However, non-traumatic inguinal hernia is mainly reported in middle aged intact female dogs, with smaller breeds being over presented and is supported by multiple etiological hypothesis which broadly includes anatomical, hormonal and metabolic factors (Slatter, 2003). With wider and short inguinal canals, female dogs are predisposed to inguinal hernias. Excessive fat accumulation around vaginal process in obese dogs may be responsible for widening the inguinal canal (Sontas *et al.*, 2013). In addition to this anatomical factor, sex hormones, mainly estrogen are said to be responsible for changing elasticity of connective tissue leading to weakening of muscles during estrous and pregnancy and hence, cases are being presented immediately after estrus or parturition. This study reports the physical, ultrasonographical and surgical findings of 9 female dogs presented with inguinal swelling.

MATERIALS AND METHODS

This particular communication is about the intact female dogs (n=9) presented to the teaching veterinary hospital at an

Department of Veterinary Surgery & Radiology, College of Veterinary Science, Guru Angad Dev Veterinary & Animal Sciences University, Ludhiana-141004, Punjab, India

Corresponding Author: Nikita Gupta, Department of Veterinary Surgery & Radiology, College of Veterinary Science, Guru Angad Dev Veterinary & Animal Sciences University, Ludhiana-141004, Punjab, India. e-mail: guptanikita086@gmail.com

How to cite this article: Gupta, N., Sangwan, V., Kumar, A., Anand, A., & Mahajan, S. K. (2025). Inguinal Hysterocele Mimics Mammary Tumour in Small Breed Dogs. *Ind J Vet Sci and Biotech*. 21(1), 106-109.

Source of support: Nil

Conflict of interest: None

Submitted 17/09/2024 **Accepted** 09/11/2024 **Published** 10/01/2025

institute level with the primary complaint of inguinal swelling on the left side (Table 1; Fig. 1). There was no history of trauma or recent parturition correlating to the swelling. All the dogs had normal feed and water intake and normal urination and defecation. One female dog of non-descript breed also had the history of vaginal discharge at presentation.

All the dogs belonged to middle age (5-9 yrs), except 2 dogs which were young (3 and 2.5 yrs). The dogs were of small breed (3 Dachshund, 2 Pug, 2 Pomeranian, 2 mix breed) and the body weight varied from 8-15 kg, except the non-descript breed with body weight of 22 kg. The mean duration of swelling was 16.62±16.05 months and the dogs otherwise had no problem with the swelling. All the dogs presented had left inguinal swelling and a 2.5 years old ND

Table 1: The detailed signalment, ultrasonographic and surgical findings in female dogs with inguinal swelling

Case No.	Breed	Age in years	Body weight in kg	Duration of inguinal swelling	Ultrasonographic findings	Surgical findings
1	Dachshund (Fig. 1b)	7	8	2 years	Intestinal loops with motility and hyper-echoic lumen and loop with anechoic lumen	Pyometric uterus was herniated. Ovario-hysterectomy done, Intestines reposed Hernia repaired
2	Dachshund	3	10	6 months	Intestinal loops and uterine horn (1.1 cm in diameter) seen in the herniated mass, spleen appeared moderately enlarged	Ovario-hysterectomy done and intestinal loops reposed
3	Dachshund	7	11	6 months	Heterogenous echotexture	Part of broad ligament herniated; Ovario-hysterectomy done (Fig. 3a, c)
4	Pug (Fig. 1d)	7	9.8	11 months	Non motile loops with anechoic lumen	Uterus was herniated and ovario-hysterectomy was done (Fig. 3b, d)
5	Pug	5	11.5	1 year	Heterogenous echotexture	Part of broad ligament herniated; Ovario-hysterectomy done
6	Pomeranian (Fig. 1c)	8	15	6 months	Non motile loops with anechoic lumen	Broad ligament and uterus herniated; ovario-hysterectomy was done
7	Pomeranian	9	12	4 years	Heterogenous echotexture	Part of broad ligament herniated; Ovario-hysterectomy done
8	Non-descript	2.5	22	20 days	Non motile loops with anechoic lumen	Pyometric uterus removed
9	Non-descript	8	8.5	3 years	Anechoic cavity corresponding to urinary bladder	Uterus and urinary bladder were found to be herniated, hernial sac was filled with sero-sanguinous fluid which was drained, bladder reposed and ovariohysterectomy done

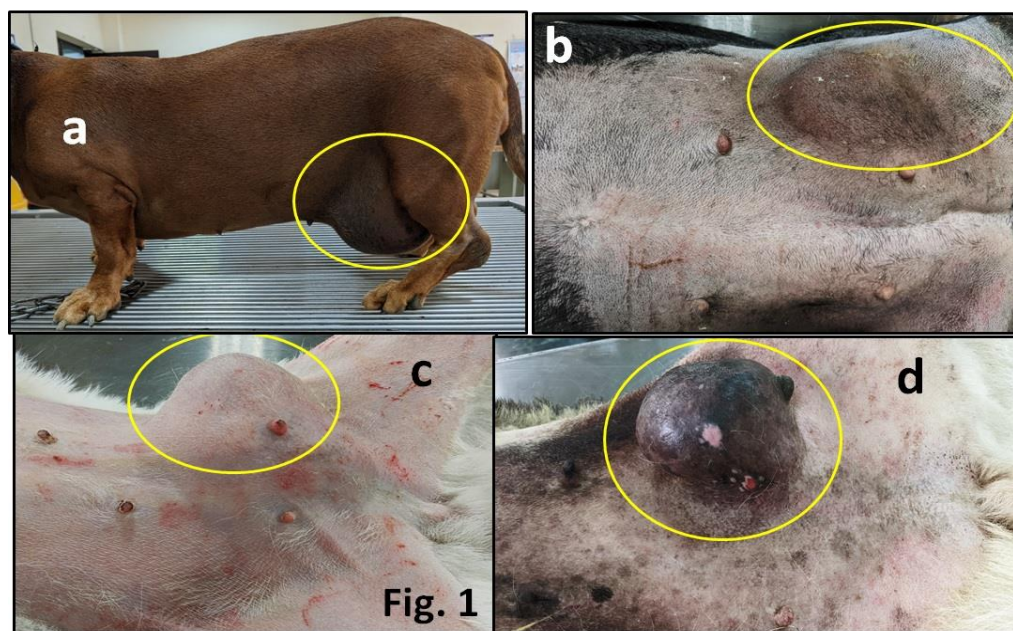


Fig. 1: Photographs showing the clinical presentation of left side inguinal hysterocele in a Dachshund dog (a), left side inguinal hysterocele in another Dachshund dog (b), left inguinal hysterocele in a Pomeranian (c) and Left inguinal hysterocele in a Pug dog (d). The circle (yellow) depicts the hernia.

dog also had purulent vaginal discharge in concurrence with inguinal swelling (Table 1).

Haemato-Biochemistry Findings

Complete blood count (CBC) and serum creatinine were evaluated in all the dogs. The serum creatinine was within

the normal range in all the dogs. The CBC was also within the normal range for all the dogs, except two, where the TLC was 57,700 (7 yr dachshund) and 21,100 (ND dog with vaginal discharge). The haemoglobin was 8.9 g/dL in both the dogs.

Radiography and Ultrasonography

The chest radiograph in all the dogs was negative for metastasis and mild to moderate broncho-interstitial pattern was seen in 4 dogs. The caudal abdominal radiograph was done in 2 dogs. Case 2, revealed a soft tissue opacity and gas filled intestinal loops in the inguinal region with a continuity from abdomen (Fig. 2).

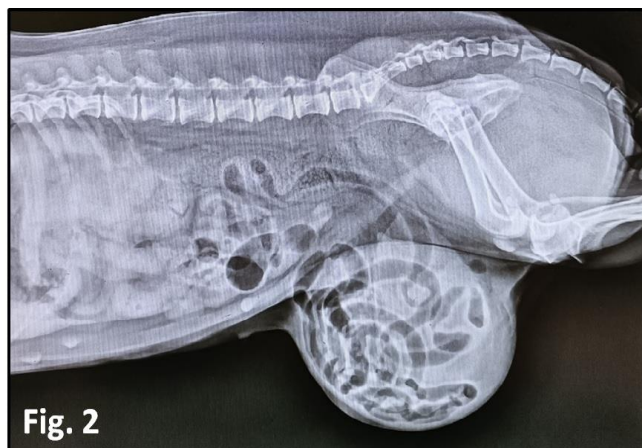


Fig. 2

Fig. 2: Lateral radiograph of caudal abdomen showing a soft tissue opacity in inguinal region with some soft tissue opacities and few gas loops, which are continuous with the abdominal loops.

Ultrasonography of the swelling was done in all the dogs which revealed presence of small intestines with motility in 2 dogs (33.33%) confirming inguinal hernia, while in rest of the dogs heterogenous opacity or round loops with some anechoic contents were visualized (Table 1).

SURGICAL TREATMENT AND DISCUSSION

All the dogs were operated for inguinal swelling under general anesthesia. The preanesthetic (xylazine @ 1 mg/kg body weight and atropine sulphate @ 0.04 mg/kg, Intramuscular) and induction agent (propofol @ 2-3 mg/kg, slow IV) were given at an interval of 10 min. The dogs were intubated with a proper size tubes and were further maintained on isoflurane mixed in 100% oxygen. The dogs were positioned in ventro-dorsal position and were aseptically prepared. The surgical procedure involved incision over the swelling, followed by careful subcutaneous dissection to reveal the contents. The peritoneal sac was found thickened and most of the dogs had fluid filled sac which drained as soon as it was opened. The details of the content of hernia are mentioned in Table 1. In all the dogs, ovario-hysterectomy was done from same incision following standard procedure (Fossum, 2018). Four out of 9 dogs required a further cranial extension of the ring to remove the ovaries properly. The other hernia contents were also reposed and the hernial ring was sutured using PDS No. 2-0 or 0 depending upon the size of dog (Fig. 3). Subcutaneous and skin incision was closed routinely. All the dogs recovered uneventfully.

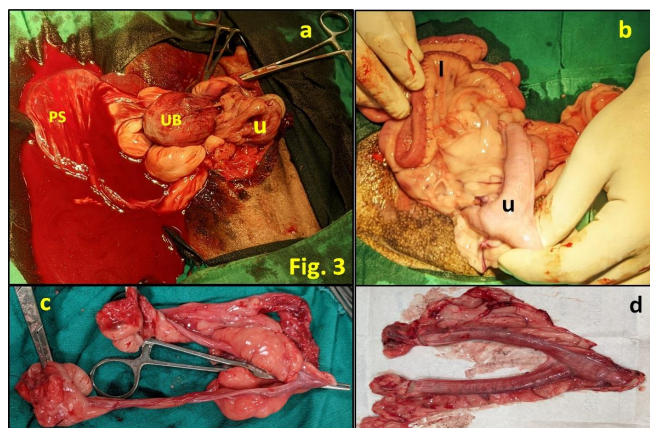


Fig. 3: Photographs showing a herniated uterus (u), urinary bladder (UB) and the peritoneal sac (PS) (a) and the removed ovaries and uterus (c) in a dachshund dog. Photographs showing herniated uterus (u), and intestines (I) (b) and the removed ovaries and uterus (d) in a pug dog.

Post-operatively all the dogs were given antibiotics, inj. Cefataxime @ 20 mg/kg, twice daily for 5 days and analgesic, inj. meloxicam @ 0.2 mg/kg, once daily for 5 days. The surgical wound was dressed with betadine as per requirement. The skin sutures were advised to be removed after 10 days. All the dogs were reported healthy at 15-30 days follow up.

Inguinal swelling in a female dog has the differentials of mammary tumour, abscess and inguinal hernia (Noakes, 2001). Radiography and ultrasonography may be done for confirmatory diagnosis. Ultrasonography uses the principle of motility for confirming inguinal hernia as intestines are more commonly herniated. But, if omentum, broad ligament or uterus is herniated which are the immotile abdominal organs, motility is not seen on ultrasonography and hernia cannot be confirmed. Inguinal hernias in dogs also have the anechoic contents in the herniated peritoneum, which is usually increased peritoneal fluid due to partial strangulation. Needle aspiration may be avoided for cytology if suspected herniation as it may go into the pyometric uterus. In the present study also, 3 out of 9 dogs (33.33%) had only heterogeneous material seen on ultrasound and could not be confirmed for hernia, while another dogs with immotile loops were also doubtful. Surgery is mandatory for all types of abnormal inguinal swelling in a female dog and only it can confirm the diagnosis. Ovario-hysterectomy is recommended if uterus is a part of hernia contents (Itoh *et al.*, 2020). Sometimes, the herniated uterus may be pyometric (Nak *et al.*, 2004) and when its size increases leads to strangulation and the dog may feel pain with it, which is otherwise not present and may be the reason for the chronicity of the condition. Similar manifestation may be present with intestinal strangulation. Needle aspiration in the inguinal hernia, may contaminate the cavity and the otherwise clear fluid of peritoneum may convert to infected fluid. The blood picture of the dog may vary as per the herniated contents for example the TLC may be elevated in case of pyometra (Simpson *et al.*, 1998; Smith, 2006), infected peritoneal fluid or intestinal strangulation.

Inguinal hernia, according to already published literature is over-presented in small breeds of dogs (Slatter, 2003), however, no breed predisposition has been reported. The inguinal hysterocele in middle age intact female dogs is usually unilateral and non-traumatic (Phillip *et al.*, 2019), but may be presented at an early age/congenital. Any small breed intact female presented for inguinal swelling should be suspected for hysterocele irrespective of pre-operative diagnostic findings (Byres *et al.*, 2007).

The left side inguinal hysterocele is more common (Serin *et al.*, 2009; Sharma *et al.* 2021). In this particular study ovariohysterectomy was performed from the hernial ring and no separate ventral midline incision was given for the procedure, although literature reports making only a midline linea alba incision to correct inguinal hernia after sufficient subcutaneous dissection, as this approach facilitates evaluation of both the inguinal canals simultaneously (Sainulabeen *et al.*, 2016; Mahesh *et al.*, 2021). The incidence of inguinal hernia increases after estrus and pregnancy (Slatter, 2003). The pyometra sometimes develops after herniation due to retention of uterus and its infection.

In conclusion, non-traumatic inguinal swelling in a middle aged intact female dog of small breed should have hysterocele as a major differential as it changes the approach to surgery. Ovario-hysterectomy is recommended in all inguinal hernia dogs with uterus or broad ligament as part of hernial content.

ACKNOWLEDGEMENT

The authors are thankful to the Head of the Department of Veterinary Surgery and Radiology and to Guru Angad Dev Veterinary and Animal Sciences University, Ludhiana, India for the facilities provided to conduct the surgeries.

REFERENCES

- Bojrab, M.J., Waldron, D.R., & Toombs, J.P. (2014). *Current Techniques in Small Animal Surgery*, 5th edn. Teton New Media.
- Byers, C.G., Williams, J.E., & Saylor, D.K. (2007). Pyometra with inguinal herniation of the left uterine horn and omentum in a Beagle dog. *Journal of Veterinary Emergency and Critical Care*, 17(1), 86-92.
- Fossum, T.W. (2018). *Small Animal Surgery-Inkling Enhanced E-Book: Small Animal Surgery E-Book*. Elsevier Health Sciences.
- Itoh, T., Kojimoto, A., Kojima, K., & Shii, H. (2020). Retrospective study on clinical features and treatment outcomes of nontraumatic inguinal hernias in 41 dogs. *Journal of the American Animal Hospital Association*, 56(6), 301.
- Mahesh, V., Yashvanth, A.N., Bhumika, P.K., & Nagaraja, B.N. (2021). Inguinal hysterocele with pyometra in a dachshund dog. *Indian Journal of Canine Practice*, 13(1), 43-46
- Nak, Y., Misirlioglu, D., Nak, D., Tuna, B., Kumru, I.H., & Alasonyalilar, A. (2004). Findings of focal adenomyosis in a case of inguinal hysterocele accompanied with mammary tumour in a bitch. *Uludag Üniversitesi Veteriner Fakültesi Dergisi*, 23, 99-102.
- Noakes, D.E. (2001): Maternal dystocia: Causes and treatment. In: Noakes D.E., Parkinson T.J., England G.C.W. (eds.): *Arthur's Veterinary Reproduction and Obstetrics*. WB Saunders, Philadelphia, p. 240-241.
- Philip, L.M., Prabhukumar, M.D., John, M.K., Dileepkumar, K.M., Nair, S.S., Venugopal, S.K., ... & Devanand, C.B. (2019). Inguinal hernia and its management in dogs: A review of eight cases. *Indian Journal of Canine Practice*, 11 (2), 171-174
- Sainulabeen, S., Nair, S., Satheesan, K., & Devanand. (2016). Inguinal hysterocele and its surgical management in a female dachshund dog. *Malaysian Journal of Veterinary Research*, 7 (2), 31-34.
- Serin, G., Yaygingul, R., Tarimcilar, T., & Sarierler, M. (2009). An incarcerated inguinal hysterocele in a pregnant bitch: A case report. *Veterinárni Medicína*, 54(8), 382-386.
- Sharma, S., Chaudhary, R.N., Tiwari, D.K., Arora, N., Niwas, R., & Bhardwaj, V. (2021). Ventral epiplo-hysterocele in a pug. *The Haryana Veterinarian*, 60(SI), 97-98
- Simpson, G.M., England, G.C., & Harvey, M. (Eds.). (1998). *BSAVA Manual of Small Animal Reproduction and Neonatology*, 2nd edn., British Small Animal Veterinary Association, Shurdington, Cheltenham, U.K..
- Slatter, D.H. (Ed.). (2003). *Textbook of Small Animal Surgery*, Vol. 1. Elsevier Health Sciences.
- Smith, F.O. (2006). Canine pyometra. *Theriogenology*, 66(3), 610-612.
- Sontas, B.H., Toydemir, F.S., Erdogan, Ö., Şennazli, G., & Ekici, H. (2013). Inguinal herniation with hydrometra/mucometra in a Poodle bitch. *The Canadian Veterinary Journal*, 54(9), 840.