

EFFICACY OF AN HERBAL FORMULATION FOR WOUND HEALING MANAGEMENT IN CATTLE

S. Peer Mohammed, M. Sundaramari, N. Punniamurthy and A. Ramanathan

Veterinary University Training and Research Centre Dindigul - 624 001

ABSTRACT

The results of the present study indicated that the herbal ointment enhanced healing of septic wounds in cattle. This prohealing effect is comparable to that of commercial povidone ointment and could be attributed to tissue proliferating and antibacterial activity of the constituent herbs. The herbal ointment was found to be cost effective since it is prepared from locally available herbs with indigenous techniques.

KEY WORDS : Efficacy, Herbal formulation , wound , cattle

INTRODUCTION

Although wound healing is essentially a physiologic process, wound infection resulting from exposure or poor hygiene is one of the most commonly encountered and clinically important impediments to wound healing in livestock. Topical antibiotics and antiseptics are widely used but are very expensive and have the disadvantage of weakening the cell membrane, toxic and irritating action at the point of application, development of resistant pathogens and concerns regarding antibiotic and chemical residues in meat. Traditionally, medicinal plants have been used for many years as topical preparations to promote wound repair. Plant extracts have been shown to possess tissue proliferating (*Curcuma longa*, *Aloe vera*), antimicrobial (*Aristolochia bracteata*, *Azadirachta indica*), anti-inflammatory (*Curcuma longa*), fly repellent (*Azadirachta indica*) and soothing (*Aloe vera*, *Azadirachta indica*) properties. Therefore a combination of these plants may exert overall beneficial effect in wound healing. Hence, the present study was carried out to develop and evaluate a ready to use herbal ointment formulation using locally available herbs for the treatment of septic wounds in cattle.

MATERIALS AND METHODS

The herbal ointment was prepared by using *Aloe vera* pulp (1kg), *Aristolochia bracteata* leaf extract (1 litre), *Curcuma longa* rhizome powder (70 g), Neem oil (1 litre) and honey wax (220 g). Fresh leaves of *Aristolochia bracteata* were made into a paste by grinding in wet grinder. The paste was taken in clean cloth and squeezed to get the extract. One litre of neem oil was added to one litre of extract and mixed thoroughly. This mixture was heated in a gas stove till the water got evaporated completely. The mixture was again filtered using a clean white cloth for removing the sediment. *Curcuma longa* powder, pulp of *Aloe vera* and honey wax were then added and thoroughly mixed. The entire mixture was again heated gently in low flame till the wax got melted. After cooling the mixture to room temperature, the ointment was packed in 50g sterile plastic containers. The clinical trial was carried out in 60 cases of cattle of either sex and upto 5 years of age with septic wounds. The cases were randomly divided into two groups of 30 each. After cleaning with normal saline, the wounds were dressed with herbal formulation in group I cattle and povidone iodine ointment in group II cattle which served as control group. Healing of the wound was judged clinically by observing the appearance of wound, degree of inflammation and time taken for wound closure. Photographic appearance of the wound was recorded on the day of presentation and on 6th, 9th, 12th and 15th post treatment days (Plate 1).

RESULTS AND DISCUSSION

On the day of presentation clinical observation revealed pus formation (70.00%), presence of foreign matter (26.67%) and necrotic tissue (16.67%) on the wound surface. The appearance of the wound at different time intervals is given in plate 1. The dark red colour of the wounds on the day of presentation turned to pink red and pinkish white respectively on 7th & 10th post treatment days in group I and 8th and 12th post treatment days in group II. The change of colour to pinkish white is suggestive of the progress of wound healing. The wound became pinkish white two days earlier in group I than in group II which is indicative of faster healing in animals treated with herbs than with povidone iodine ointment.

Moderate swelling at the periphery of the wound and pain on digital pressure noticed up to day 3 in both groups reduced gradually and disappeared on the 6th day. The early disappearance of the edema and pain in group I could be attributed to anodyne property of neem oil (Hoque and Bhargava, 1988) and anti-inflammatory activity of essential oils of *Curcuma longa*.

Antibacterial activities of *Aristolochia bracteata* (Negi *et al.*, 2003; Manikandan *et al.*, 2006) neem oil (Thaker and Anjaria, 1986; Ahmad *et al.*, 1995) and *Aloe vera* (Agarry *et al.*, 2005) have been proved in several laboratory studies. Disappearance of pus on the wound surface from the 3rd post treatment day in the present study confirms the antibacterial property of the herbal ointment.

Formation of granulation tissue was evident on 4th to 5th post treatment day on both groups which indicates that wound healing property of the herbal ointment is comparable with that of control group of povidone iodine ointment. Faster appearance of granulation tissue in group I could be attributed to tissue proliferating property of curcumin including increased migration of myofibroblasts, fibroblasts, and macrophages and neovascularization in the wound bed (Deshpande, 1984 and Sidhu *et al.*, 1998) and to the stimulant action of *Aloe vera* on collagen synthesis as well as its degree of cross linking (Chithra *et al.*, 1998).

The mean time taken for complete healing of wound was 15.84 days in group I and 17.12 days in group II animals. The rapid closure of wounds in animals treated with herbal ointment could be attributed to stimulant action of neem oil on epithelialization and keratinization (Bharadwaj and Sharma, 1997).

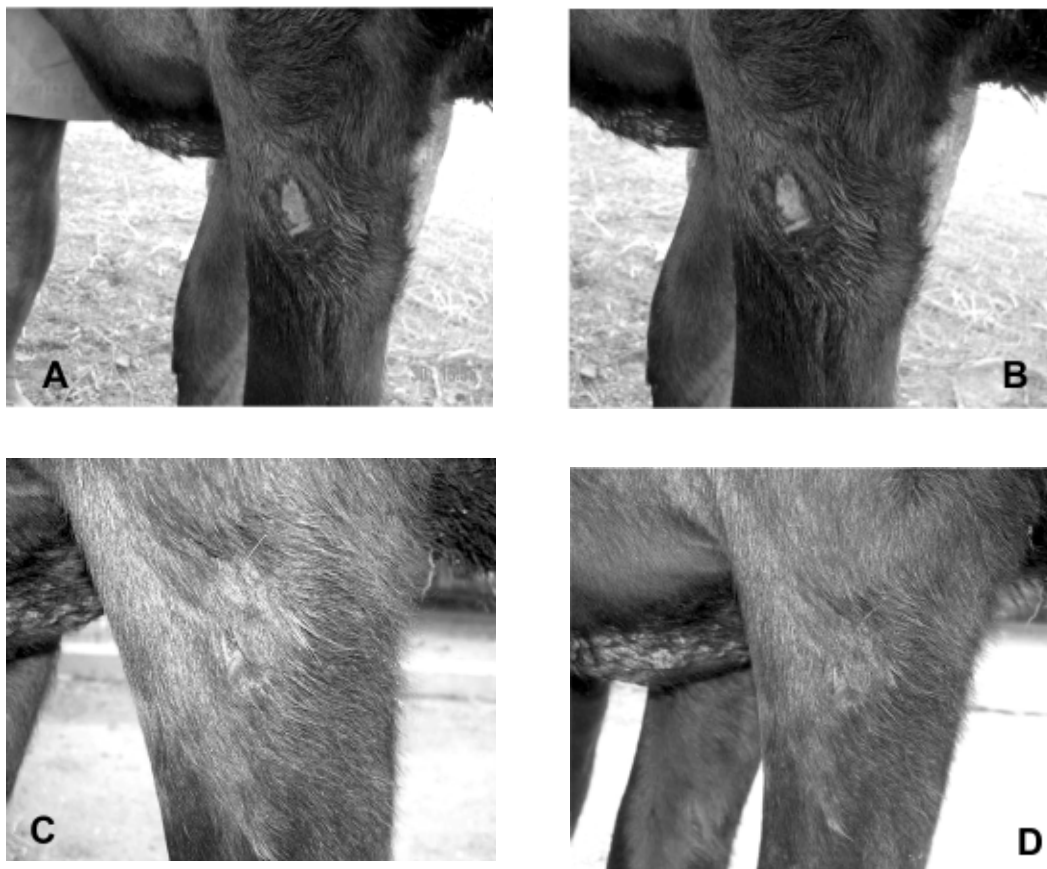


Plate 1 . Appearance of the wound in a heifer treated with ointment of herbal formulation on day 6 (A), 9 (B), 12 (C), and 15 (D)

REFERENCES

- Agarry, O.O., Olaleye M.T and Bello-Michael C.O. (2005). *African Journal of Biotechnology*, **4(12)**: 1413-1414.
- Ahmad, I., Ahmed F. and Hussain S.. (1995). *A. Juss . Indian Vet. J.*, **19(3)** 204-206.
- Bhardwaj, R.L. and Sharma D.N. (1997). *Indian Vet. Med. J .*, **21**: 187-190.
- Chithra, P., Sajithlal G.B. and Chandrakasan ,G. (1998). *Mol. Cell Biochem.*, **181(1-2)**: 71-76.
- Deshpande, V.S. (1984). Experimental studies on the effect of turmeric ointment on wound healing in crossbred cow calves. *M.V.Sc. Thesis (Unpub.)*, Dr. Panjabrao Krishi Vidyapeeth, Akola.
- Hoque, M. and Bhargava, A.K. (1988). *Ind. J. Vet. Surg.*, **9(2)**: 165.
- Manikandan, R.V., Selvamani, P and Latha ,S. (2006). *Indian Journal of Pharmaceutical Sciences*, **68(4)**: 509-510.
- Negi, P.S., Anandharamakrishnan, C and Jayaprakasha, G.K.. (2003). *J. Med. Food.*, **6(4)**: 401-403.
- Sidhu, G.S., Singh, A.K., Thaloor, D. Banaudha, K.K., Patnaik , G.K., Simal , R.C and Maheshwari , R.K. (1998). *Wound Repair and Regeneration*, **6(2)**: 167-177.
- Thaker, A.M. and Anjaria., J.V (1986). *Indian J. Pharmacol.*, **18(1)**: 171-174.

□