

Management of Cutaneous Squamous Cell Carcinoma (Clear Cell Variant) in Bovine - A Case Report

Ankit S. Prajapati^{1*}, Prakash M. Chauhan¹, Samir H. Raval²

Ind J Vet Sci and Biotech (2023): 10.48165/ijvsbt.19.5.27

Tumors of the bovine gastrointestinal tract are rare, possibly because of the low age of the sample population (Bertone, 1990). Neoplasia in cattle carries a poor prognosis because of early adenocarcinoma metastasis and the high fatality of lymphosarcoma. Squamous cell carcinoma is the second most rude type of skin cancer, with basal cell carcinoma being the most common (Rinker *et al.*, 2001). Squamous cell carcinoma has been documented in bovine (Musser *et al.*, 1993). Clear-cell squamous cell carcinoma is a rare variant of squamous cell carcinoma, first described by Kuo (1980) as a skin tumor. The exact etiology is unclear, but ultraviolet radiation has been suggested as a possible cause in humans (Lawal *et al.*, 2013). This report documents a case of cutaneous squamous cell carcinoma (clear cell variant) in perianal region of a cow and its successful surgical management.

CASE HISTORY AND OBSERVATION

A six-year-old Holstein Friesian cow was reported at Dr. V.M. Jhala Clinical Complex of Veterinary College, Deesa, Banaskantha, with a history of two masses at the perineal region for the last six months (Fig. 1). A round tennis ball-like encapsulated mass was present on gross examination with the narrow neck at the right side of the anus. At the same time, another mass was present at the right vulvar lip with cauliflower-like irregular dried edges. The owner was advised surgical intervention to remove both masses.

SURGICAL MANAGEMENT AND DISCUSSION

Surgery was performed to remove the mass from both the locations under local anaesthesia. The cow was restrained in trevis in standing position. The hairs from the affected part were removed and washed with the aseptic solution. Epidural anaesthesia was achieved by infusing 4 mL of 2% lignocaine hydrochloride and infiltrating locally around the masses. The elliptical skin incisions were made at the respective locations, and the masses were removed (Fig. 2). After removing the masses, subcutaneous and skin sutures were taken through a routine method (Fig. 3). The masses measured about 2 inches and 4 inches (Fig. 4).

¹Department of Veterinary Clinics, College of Veterinary Science and Animal Husbandry, Kamdhenu University, Sardarkrushinagar-385506, Gujarat, India

²Department of Veterinary Pathology, College of Veterinary Science and Animal Husbandry, Kamdhenu University, Sardarkrushinagar-385506, Gujarat, India

Corresponding Author: Ankit S. Prajapati, Department of Veterinary Clinics, College of Veterinary Science and Animal Husbandry, Kamdhenu University, Sardarkrushinagar-385506, Gujarat, India, e-mail: ankitprjpt1@gmail.com

How to cite this article: Prajapati, A.S., Chauham, P. M., & Raval, S. H. (2023). Management of Cutaneous Squamous Cell Carcinoma (Clear Cell Variant) in Bovine - A Case Report. *Ind J Vet Sci and Biotech*. 19(5), 121-122.

Source of support: Nil

Conflict of interest: None

Submitted: 12/07/2023 **Accepted:** 26/08/2023 **Published:** 10/09/2023



Fig. 1: Presence of two masses at the perineal region

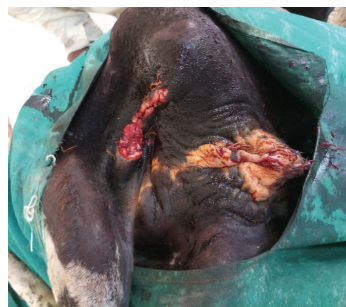

Fig. 2: Surgical management of tumor

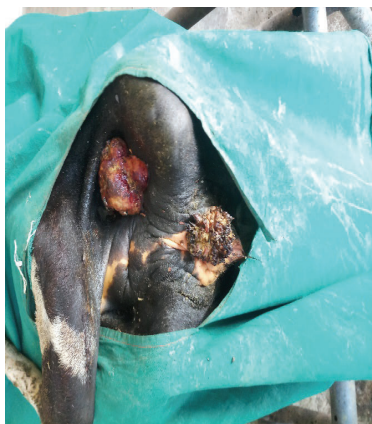

Fig. 3: Skin suture after mass removal

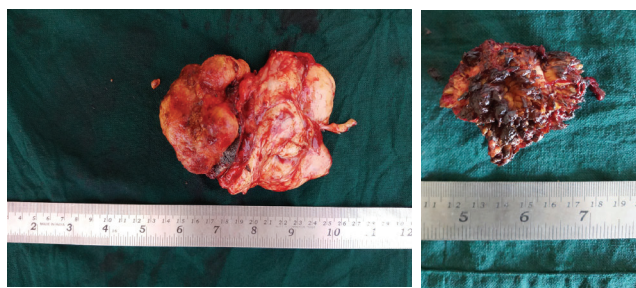


Fig. 4: Tumor mass

The tissue from both masses was collected in a separate 10% formaldehyde solution for histopathological evaluation. The histopathological examination revealed squamous cell carcinoma (SCC), neoplastic cells were arranged in variable size islands/keratin pearl supported by fibrovascular stroma. Neoplastic cells were big and polygonal with distinct cell membranes and clear and ample cytoplasm. The interstitium showed variable degrees of mononuclear cell infiltration (Fig. 5).

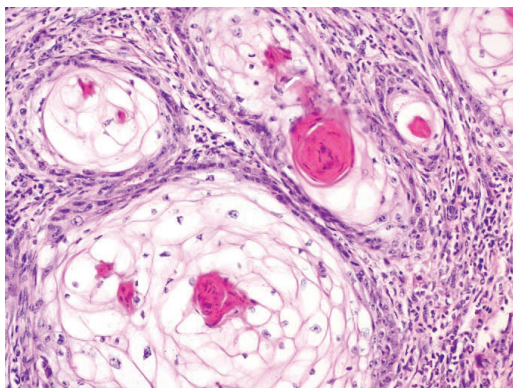


Fig. 5: Squamous cell carcinoma (Clear cell variant)

Clear cell SCC is a scarce variant of SCC. It is commonly referred to as hydropic SCC due to the extensive hydropic degeneration of neoplastic cells and the accumulation of intracellular fluid. Othmane *et al.* (2022) also described clear cell SSC as the hydropic degeneration of neoplastic cells and the collection of intracellular fluid, not glycogen, lipid, or mucin that produces a clear cell appearance. Stein

et al. (2019) reported a clear cell variant of squamous cell carcinoma from the equine eyelid and concluded that the condition had not been in animals earlier. Variants of SCC with clear cells have been described in dogs but have not been classified as clear-cell SCC. Wilson (1994) successfully managed perianal squamous cell carcinoma with permanent colostomy in a mare. Cutaneous SCC is usually easily treatable and has the potential to reoccur locally and even metastasize, then leading to significant morbidity and mortality (Rinker *et al.*, 2001). Identifying aggressive tumors requires closer monitoring, and possible adjunctive treatments such as invasive surgery or radiation therapy. A typical case has been reported by Musser *et al.* (1993) from a 15-year-old light-colored Longhorn bull. A 3 cm diameter tumor was documented around the anal region, which was histologically confirmed as isolated squamous cells deep in the dermis and submucosal connective tissue.

In conclusion, clear cell variants of squamous cell carcinoma are rare conditions in cattle. Surgical correction is required for the management. Histopathological identification aids in ruling out the nature of the tumor and predicting the tumor recurrence chances.

ACKNOWLEDGMENTS

The authors acknowledge the Principal, Veterinary College, Kamdhenu University, Sardarkrushinagar, for providing the necessary facilities.

REFERENCES

- Bertone, A.L. (1990). Neoplasms of the bovine gastrointestinal tract. *The Veterinary Clinics of North America: Food Animal Practice*, 6(2), 515-524.
- Kuo, T. (1980). Clear cell carcinoma of the skin. A variant of the squamous cell carcinoma that simulates sebaceous carcinoma. *The American Journal of Surgical Pathology*, 4(6), 573-583.
- Lawal, A.O., Adisa, A.O., Olajide, M.A., & Olusanya, A.A. (2013). Clear cell variant of squamous cell carcinoma of skin: A report of a case. *Journal of Oral and Maxillofacial Pathology*, 17(1), 110-112.
- Musser, J.M., Russell, K.E., Veatch, J.K., & St-Jean, G. (1993). Squamous cell carcinoma of the anal and perianal area in a bull. *The Cornell Veterinarian*, 83(1), 83-88.
- Othmane, B., Rajaa, E., & Malik, B. (2022). Clear cell variant of squamous cell carcinoma of skin: A case report and review of the literature. *Journal of Surgical Case Reports and Images*, 5(4), 1-4.
- Rinker, M.H., Fenske, N.A., Scalf, L.A., & Glass, L.F. (2001). Histologic variants of squamous cell carcinoma of the skin. *Cancer Control: Journal of the Moffitt Cancer Center*, 8(4), 354-363.
- Stein, L., Sledge, D., Smedley, R., Kiupel, M., & Thaiwong, T. (2019). Squamous cell carcinoma with clear cell differentiation in an equine eyelid. *Journal of Veterinary Diagnostic Investigation*, 31(2), 259-262.
- Wilson, D.A. (1994). Management of perianal squamous cell carcinoma with permanent colostomy in a mare. *Journal of the American Veterinary Medical Association*, 205(10), 1430-1431.